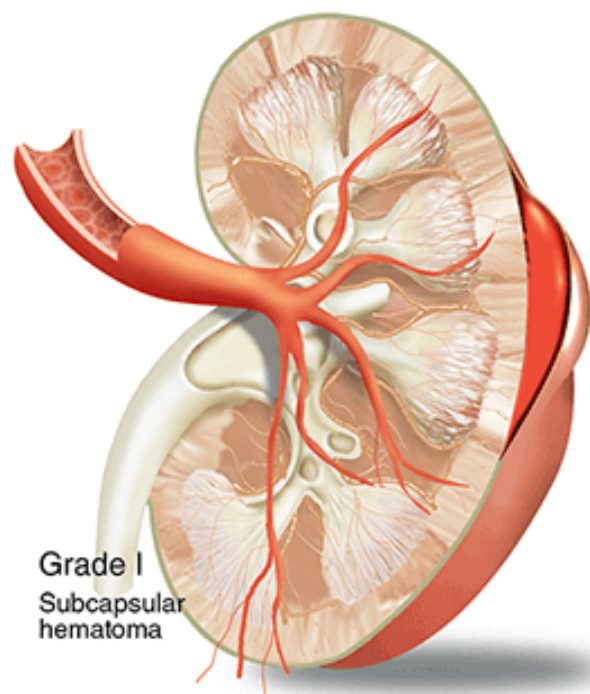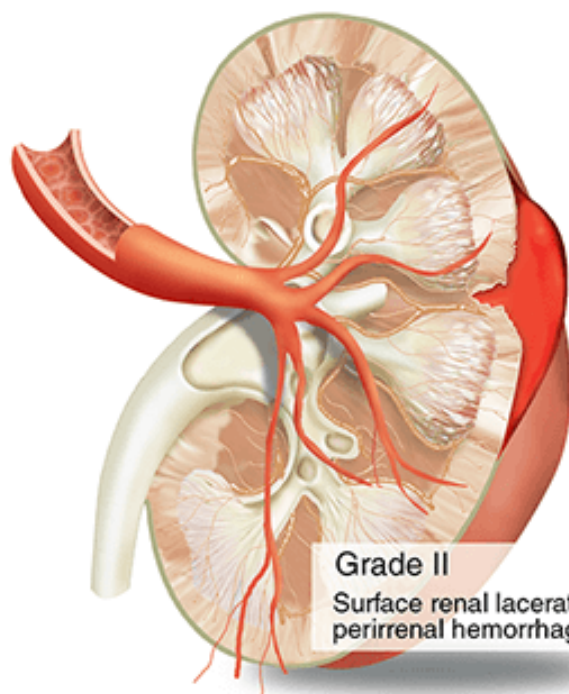
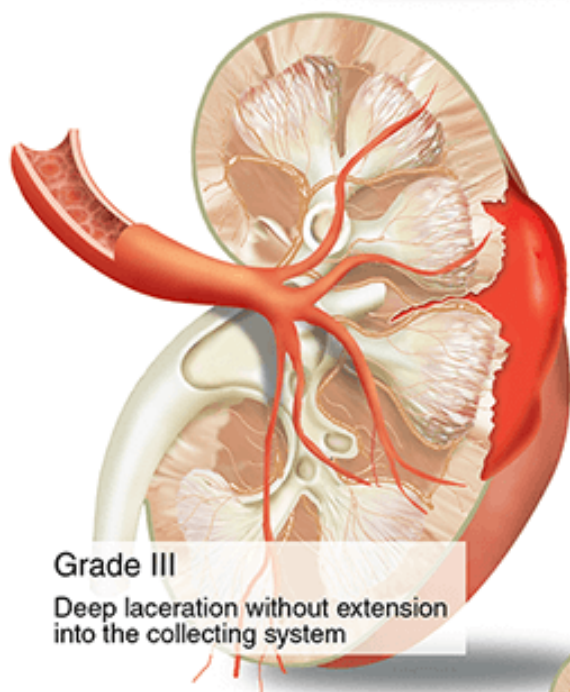


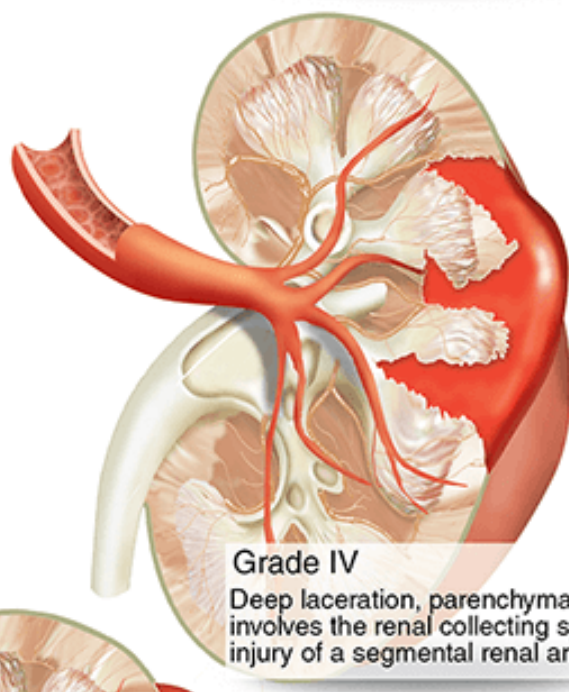
Grade I
Subcapsular
hematoma



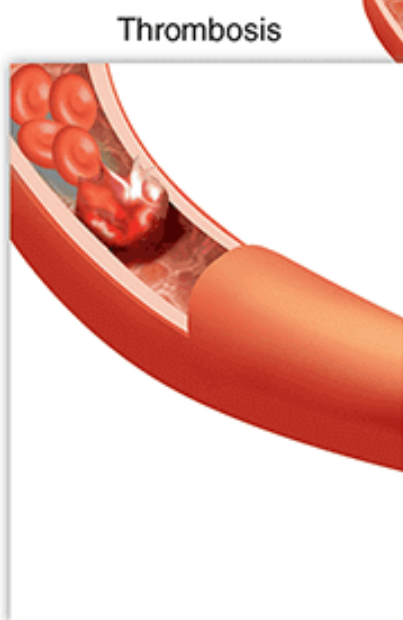
Grade II
Surface renal laceration with
perirenal hemorrhage



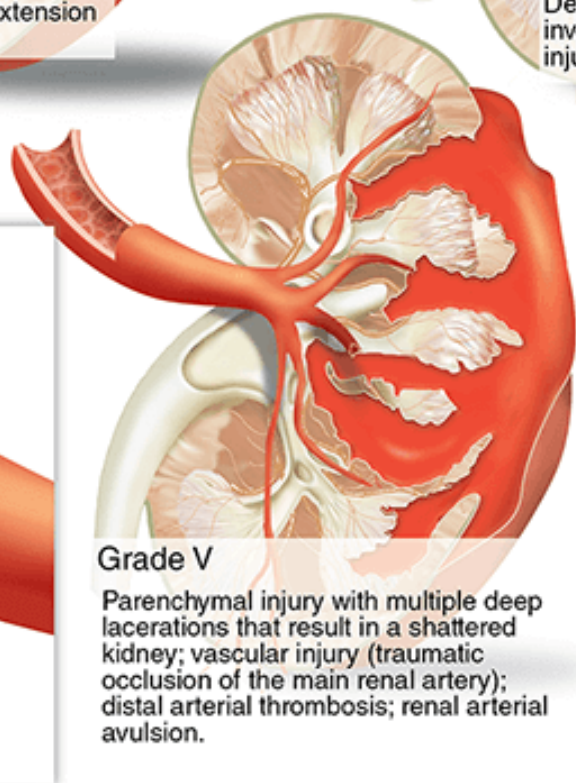
Grade III
Deep laceration without extension
into the collecting system



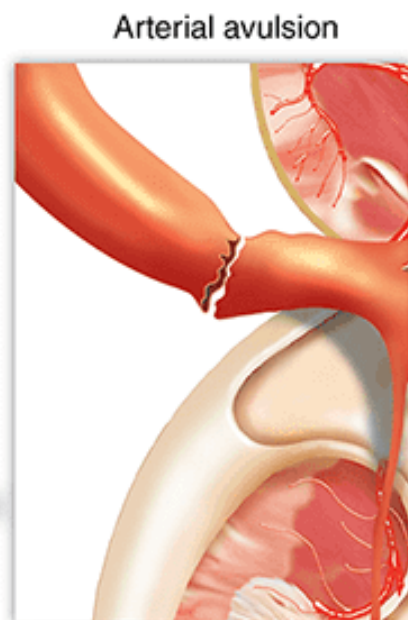Grade IV
Deep laceration, parenchymal injury that
involves the renal collecting system; vascular
injury of a segmental renal arterial branch



Thrombosis



Grade V
Parenchymal injury with multiple deep
lacerations that result in a shattered
kidney; vascular injury (traumatic
occlusion of the main renal artery);
distal arterial thrombosis; renal arterial
avulsion.



Arterial avulsion