

Guidelines on Urological Trauma

D.J. Summerton (chair), N. Djakovic, N.D. Kitrey, F.E. Kuehhas,
N. Lumen, E. Serafetinidis, D.M. Sharma

TABLE OF CONTENTS

PAGE

| | | |
|---------|---|----|
| 1. | BACKGROUND | 6 |
| 1.1 | Methodology | 6 |
| 1.1.1 | Evidence sources | 6 |
| 1.1.2 | Publication history | 6 |
| 1.1.3 | Potential conflict of interest statement | 7 |
| 1.2 | Definition and Epidemiology | 7 |
| 1.2.1 | Genito-Urinary Trauma | 7 |
| 1.2.2 | Classification of trauma | 7 |
| 1.2.3 | Initial evaluation and treatment | 8 |
| 1.3 | References | 8 |
| 2. | RENAL TRAUMA | 9 |
| 2.1 | Introduction | 9 |
| 2.2 | Mode of injury | 9 |
| 2.2.1 | Blunt renal injuries | 9 |
| 2.2.2 | Penetrating renal injuries | 10 |
| 2.2.3 | Injury classification | 10 |
| 2.3 | Diagnosis | 10 |
| 2.3.1 | Patient history and physical examination | 10 |
| 2.3.1.1 | Recommendations | 11 |
| 2.3.2 | Laboratory evaluation | 11 |
| 2.3.2.1 | Recommendations | 11 |
| 2.3.3 | Imaging: criteria for radiographic assessment | 11 |
| 2.3.3.1 | Ultrasound (US) | 12 |
| 2.3.3.2 | Intravenous pyelography (IVP) | 12 |
| 2.3.3.3 | One-shot intra-operative IVP | 12 |
| 2.3.3.4 | Computed tomography (CT) | 12 |
| 2.3.3.5 | Magnetic resonance imaging (MRI) | 13 |
| 2.3.3.6 | Angiography | 13 |
| 2.3.3.7 | Radionuclide scans | 13 |
| 2.3.3.8 | Recommendations | 13 |
| 2.4 | Treatment | 13 |
| 2.4.1 | Indications for renal exploration | 13 |
| 2.4.2 | Interventional radiology | 13 |
| 2.4.3 | Operative findings and reconstruction | 14 |
| 2.4.4 | Non-operative management of renal injuries | 15 |
| 2.4.4.1 | Blunt renal injuries | 15 |
| 2.4.4.2 | Penetrating renal injuries | 15 |
| 2.4.5 | Recommendations | 16 |
| 2.4.6 | Post-operative care and follow-up | 16 |
| 2.4.7 | Complications | 16 |
| 2.4.8 | Recommendations | 17 |
| 2.4.9 | Renal injury in the polytrauma patient | 17 |
| 2.4.10 | Recommendations | 17 |
| 2.5 | Iatrogenic renal injuries | 17 |
| 2.5.1 | Introduction | 17 |
| 2.5.2 | Incidence and aetiology | 17 |
| 2.5.3 | Diagnosis (clinical signs, imaging) | 18 |
| 2.5.4 | Management | 19 |
| 2.5.5 | Statements and recommendations | 20 |
| 2.6 | Algorithms | 20 |
| 2.7 | References | 22 |
| 3. | URETERAL TRAUMA | 30 |
| 3.1 | Aetiology | 30 |
| 3.2 | Diagnosis | 31 |
| 3.2.1 | Clinical diagnosis | 31 |
| 3.2.2 | Radiological diagnosis | 31 |

| | | |
|---------|---|----|
| 3.3 | Prevention of iatrogenic trauma | 31 |
| 3.4 | Management | 31 |
| 3.4.1 | Uretero-ureterostomy | 32 |
| 3.4.2 | Uretero-calycostomy | 32 |
| 3.4.3 | Transuretero-ureterostomy | 32 |
| 3.4.4 | Ureteral reimplantation with a psoas hitch | 32 |
| 3.4.5 | Ureteral reimplantation with a Boari flap | 32 |
| 3.4.6 | Ileal interposition graft | 32 |
| 3.4.7 | Autotransplantation | 33 |
| 3.5 | Statements and recommendations on ureteral trauma | 33 |
| 3.6 | References | 33 |
| 4. | BLADDER TRAUMA | 35 |
| 4.1 | Background, incidence and aetiology | 35 |
| 4.1.1 | External (non-iatrogenic) trauma | 35 |
| 4.1.2 | Iatrogenic trauma | 35 |
| 4.1.2.1 | External iatrogenic bladder trauma | 36 |
| 4.1.2.2 | Internal iatrogenic bladder trauma | 36 |
| 4.2 | Risk factors | 36 |
| 4.3 | Clinical signs and symptoms | 36 |
| 4.3.1 | External trauma | 36 |
| 4.3.1.1 | Caution in case of urinary retention and/or urethral blood loss | 37 |
| 4.3.2 | Iatrogenic trauma | 37 |
| 4.3.2.1 | Peri-operative: external iatrogenic bladder trauma | 37 |
| 4.3.2.2 | Peri-operative: internal iatrogenic bladder trauma | 37 |
| 4.3.2.3 | Post-operative: unrecognized bladder injury | 37 |
| 4.3.3 | Intravesical foreign body | 37 |
| 4.4 | Imaging | 37 |
| 4.4.1 | Cystography (conventional or CT) | 37 |
| 4.4.2 | Cystoscopy | 38 |
| 4.4.3 | Excretory phase of CT or IVP | 38 |
| 4.4.4 | Ultrasound | 38 |
| 4.5 | Treatment | 38 |
| 4.5.1 | External trauma | 38 |
| 4.5.1.1 | Blunt trauma: extraperitoneal rupture | 38 |
| 4.5.1.2 | Blunt trauma: intraperitoneal rupture | 38 |
| 4.5.1.3 | Penetrating injuries | 38 |
| 4.5.1.4 | Bladder injuries with avulsion of lower abdominal wall or perineum and/or bladder tissue loss | 39 |
| 4.5.2 | Iatrogenic injuries | 39 |
| 4.5.3 | Intravesical foreign body | 39 |
| 4.5.4 | Post-operative management | 39 |
| 4.6 | Statements and recommendations | 39 |
| 4.7 | References | 40 |
| 5. | URETHRAL TRAUMA | 43 |
| 5.1 | Anterior urethral injuries | 43 |
| 5.2 | Posterior urethral injuries (in males) | 43 |
| 5.3 | Urethral injuries in females | 44 |
| 5.4 | Diagnosis in males and females | 44 |
| 5.4.1. | Clinical signs and symptoms | 44 |
| 5.4.2 | Further diagnostic techniques | 44 |
| 5.4.2.1 | Retrograde urethrography | 44 |
| 5.4.2.2 | Urethrogram | 45 |
| 5.4.2.3 | Ultrasound, CT and MR imaging | 45 |
| 5.4.2.4 | Cystoscopy | 45 |
| 5.4.2.5 | Summary | 45 |
| 5.5 | Management | 45 |
| 5.5.1 | Anterior urethral injuries | 45 |
| 5.5.1.1 | Blunt anterior urethral injuries | 45 |

| | | |
|---------------|---|----|
| 5.5.1.2 | Penile fracture-related anterior urethral injuries | 46 |
| 5.5.1.3 | Penetrating anterior urethral injuries | 46 |
| 5.6.1 | Posterior urethral injuries | 46 |
| 5.6.1.1 | Blunt posterior urethral injuries | 46 |
| 5.6.1.1.1 | Immediate management | 46 |
| 5.6.1.1.1.1 | Partial posterior urethral rupture | 46 |
| 5.6.1.1.1.2 | Complete posterior urethral rupture | 47 |
| 5.6.1.1.1.2.1 | Immediate realignment | 47 |
| 5.6.1.1.1.2.2 | Immediate urethroplasty | 47 |
| 5.6.1.1.2 | Delayed primary treatment | 47 |
| 5.6.1.1.2.1 | Delayed primary realignment | 47 |
| 5.6.1.1.2.2 | Delayed primary urethroplasty | 48 |
| 5.6.1.1.3 | Deferred treatment | 48 |
| 5.6.1.1.3.1 | Deferred urethroplasty | 48 |
| 5.6.1.1.3.2 | Deferred endoscopic treatment | 49 |
| 5.6.1.2 | Penetrating posterior urethral injuries | 49 |
| 5.6.2 | Female urethral injuries | 49 |
| 5.7 | Treatment algorithms | 49 |
| 5.8 | Statements and recommendation on trauma of the urethra | 51 |
| 5.9 | Iatrogenic urethral trauma | 52 |
| 5.9.1 | Introduction | 52 |
| 5.9.2 | Causes of iatrogenic urethral trauma | 52 |
| 5.9.2.1 | Transurethral catheterisation | 52 |
| 5.9.2.2 | Transurethral surgery | 53 |
| 5.9.2.3 | Surgical treatment for prostate cancer | 53 |
| 5.9.2.4 | Radiotherapy for prostate cancer | 54 |
| 5.9.2.5 | Major abdominal surgery and cystectomy | 54 |
| 5.9.3 | Symptoms of iatrogenic urethral injury | 55 |
| 5.9.4 | Diagnosis | 55 |
| 5.9.5 | Treatment | 55 |
| 5.10 | Statements and recommendations regarding iatrogenic urethral trauma | 55 |
| 5.11 | References | 56 |
| 6. | GENITAL TRAUMA | 61 |
| 6.1 | Introduction and background | 61 |
| 6.2 | General principles and pathophysiology | 61 |
| 6.2.1 | Gunshot wounds | 61 |
| 6.2.2 | Bites | 61 |
| 6.2.2.1 | Animal bites | 61 |
| 6.2.2.2 | Human bites | 62 |
| 6.2.3 | Sexual assault | 62 |
| 6.3 | Organ-specific genital trauma | 62 |
| 6.3.1 | Penile trauma | 62 |
| 6.3.1.1 | Blunt penile trauma | 62 |
| 6.3.1.1.1 | Penile fracture | 62 |
| 6.3.2 | Penetrating penile trauma | 63 |
| 6.3.3 | Penile avulsion injuries and amputation | 63 |
| 6.4 | Scrotal trauma | 64 |
| 6.4.1 | Blunt scrotal trauma | 64 |
| 6.4.1.1 | Testicular dislocation | 64 |
| 6.4.1.2 | Haematocoele | 64 |
| 6.4.1.3 | Testicular rupture | 64 |
| 6.4.2 | Penetrating scrotal trauma | 64 |
| 6.5 | Genital trauma in females | 65 |
| 6.5.1 | Blunt vulvar injuries | 65 |
| 6.6 | Conclusion and recommendations for genital trauma | 65 |
| 6.7 | References | 65 |

| | | |
|---------|--|----|
| 7. | POLYTRAUMA, DAMAGE CONTROL AND MASS CASUALTY EVENTS | 69 |
| 7.1 | Introduction | 69 |
| 7.1.1 | The development of major trauma centres | 69 |
| 7.1.1.1 | Recommendations for polytrauma management | 69 |
| 7.2 | Damage control | 69 |
| 7.3 | Management principles: polytrauma and associated urological injury | 69 |
| 7.3.1 | Statement and recommendation on management principles | 70 |
| 7.4 | Urological injury management in polytrauma | 70 |
| 7.4.1 | Renal injury | 70 |
| 7.4.1.1 | Renal preservation | 70 |
| 7.4.1.2 | Recommendations for the management of renal injury | 70 |
| 7.4.2 | Ureteral injury | 70 |
| 7.4.2.1 | Recommendations for the management of ureteral injury | 71 |
| 7.4.3 | Bladder trauma | 71 |
| 7.4.3.1 | Recommendations for the management of bladder trauma | 71 |
| 7.4.4 | Urethral injury | 71 |
| 7.4.4.1 | Recommendation for the management of urethral injury | 71 |
| 7.4.5 | External genital injury | 71 |
| 7.5 | Mass casualty events | 72 |
| 7.5.1 | Triage | 72 |
| 7.5.2 | Urological role in the mass casualty setting | 72 |
| 7.5.3 | Statements and recommendations for mass casualty events | 73 |
| 7.6 | References | 73 |
| 8. | ABBREVIATIONS USED IN THE TEXT | 75 |

1. BACKGROUND

The European Association of Urology (EAU) Guidelines Group for Urological Trauma prepared these guidelines in order to assist medical professionals in the management of urological trauma.

1.1 Methodology

1.1.1 Evidence sources

The Urological Trauma guidelines are based on a review of the relevant literature, using on-line searches of the following databases: Medline, Embase, Cochrane, and other source documents published between 2002 and 2013. A critical assessment of the findings was made. The majority of publications on the subject are comprised of case reports and retrospective case series. The paucity of high-powered randomized controlled trials makes it difficult to draw meaningful conclusions. The panel recognizes this critical limitation.

A level of evidence (LE) and/or grade of recommendation (GR) have been assigned where possible. The aim of grading recommendations is to provide transparency between the underlying evidence and the recommendation given.

Levels of evidence and grade of guideline recommendations*

Table 1.1: Level of evidence (1)*

| Level | Type of evidence |
|-------|---|
| 1a | Evidence obtained from meta-analysis of randomised trials. |
| 1b | Evidence obtained from at least one randomised trial. |
| 2a | Evidence obtained from one well-designed controlled study without randomisation. |
| 2b | Evidence obtained from at least one other type of well-designed quasi-experimental study. |
| 3 | Evidence obtained from well-designed non-experimental studies, such as comparative studies, correlation studies and case reports. |
| 4 | Evidence obtained from expert committee reports or opinions or clinical experience of respected authorities. |

Table 1.2: Grade of recommendation (1)*

| Grade | Nature of recommendations |
|-------|--|
| A | Based on clinical studies of good quality and consistency addressing the specific recommendations and including at least one randomised trial. |
| B | Based on well-conducted clinical studies, but without randomised clinical trials. |
| C | Made despite the absence of directly applicable clinical studies of good quality. |

* Modified from (1).

It should be noted that when recommendations are graded, the link between the level of evidence and grade of recommendation is not directly linear. Availability of RCTs may not necessarily translate into a grade A recommendation where there are methodological limitations or disparity in published results.

Alternatively, absence of high level evidence does not necessarily preclude a grade A recommendation, if there is overwhelming clinical experience and consensus. In addition, there may be exceptional situations where corroborating studies cannot be performed, perhaps for ethical or other reasons and in this case unequivocal recommendations are considered helpful for the reader. The quality of the underlying scientific evidence - although a very important factor - has to be balanced against benefits and burdens, values and preferences and costs when a grade is assigned (2-4).

The EAU Guidelines Office do not perform cost assessments, nor can they address local/national preferences in a systematic fashion. But whenever this data is available, the panel will include the information.

1.1.2 Publication history

The Urological Trauma Guidelines were first published in 2003; partial or full updates were available in 2006, 2009 and 2013. This 2014 update presents a limited update. The literature was assessed for all chapters and the texts have been condensed; Chapter 7 - Polytrauma, damage control and mass casualty events - has been completely updated.

Paediatric trauma is addressed in the paediatric urology guidelines, and not in this urological trauma document.

A quick reference document presenting the main findings of the Trauma guidelines is also available alongside several scientific publications in the EAU scientific journal *European Urology* (5,6).

All texts can be viewed and downloaded for personal use at the EAU website:

<http://www.uroweb.org/guidelines/online-guidelines/>.

1.1.3 **Potential conflict of interest statement**

The expert panel have submitted potential conflict of interest statements which can be viewed on the EAU website: <http://www.uroweb.org/guidelines/online-guidelines/>.

1.2 **Definition and Epidemiology**

Trauma is defined as a physical injury or a wound to living tissue caused by an extrinsic agent. Trauma is the sixth leading cause of death worldwide, accounting for 10% of all mortalities. It accounts for approximately 5 million deaths each year worldwide and causes disability to millions more (7,8).

About half of all deaths due to trauma are in people aged 15-45 years and in this age it is the leading cause of death. Death from injury is twice as common in males as females, especially from motor vehicle accidents (MVA) and interpersonal violence. Trauma is therefore a serious public health problem with significant social and economic costs.

Significant differences exist in the causes and the effects of traumatic injuries between geographical areas, and between low, middle, and high-income countries. It should be noted that alcohol and drug abuse increase the rate of traumatic injuries by precipitating interpersonal violence, child and sexual abuse, and motor vehicle accidents.

1.2.1 **Genito-Urinary Trauma**

Genito-urinary trauma is seen in both sexes and in all age groups, but is more common in males.

The kidney is the most commonly injured organ in the genito-urinary system and renal trauma is seen in up to 5% of all trauma cases (9,10), and in 10% of all abdominal trauma cases (11). In MVAs, renal trauma is seen after direct impact into the seatbelt or steering wheel (frontal crashes) or from body panel intrusion in side-impact crashes (12).

Ureteral trauma is relatively rare but due mainly to iatrogenic injuries, and in penetrating gunshot wounds - both in military and civilian settings (13).

Traumatic bladder injuries are usually due to blunt (MVA) causes and associated with pelvic fracture (14), although may also be a result of iatrogenic trauma.

The anterior urethra is most commonly injured by blunt or "fall-astride" trauma, whereas the posterior urethra is usually injured in pelvic fracture cases - the majority of which are seen in MVAs (15).

Genital trauma is much more common in males due to anatomical considerations and more frequent participation in physical sports, violence and war-fighting. Of all genitor-urinary injuries, 1/3-2/3rds involve the external genitalia (16).

1.2.2 **Classification of trauma**

Traumatic injuries are classified by the world health organization (WHO) into intentional (either interpersonal violence related, war-related or self-inflicted injury), and unintentional injury - mainly motor vehicle collisions, falls, and other domestic accidents. Intentional trauma accounts for approximately half of the trauma-related deaths worldwide (8). A specific type of unintentional injury consists of iatrogenic injury which is created during treatment or diagnostic procedures by healthcare personnel.

Traumatic injuries are classified according to the basic mechanism into penetrating when an object pierces the skin, and blunt.

Penetrating trauma is further classified according to the velocity of the projectile:

1. High-velocity projectiles (e.g. rifle bullets - 800-1000m/sec)
2. Medium-velocity (e.g. handgun bullets - 200-300 m/sec)
3. Low-velocity items (e.g. knife stab)

High-velocity weapons inflict greater damage because the bullets transmit large amounts of energy to the tissues. They form temporary expansive cavitation that immediately collapses and creates shear forces and

destruction in a much larger area than the projectile tract itself. Cavity formation disrupts tissue, ruptures blood vessels and nerves, and may fracture bones away from the missile path. In lower velocity injuries, the damage is usually confined to the track of the projectile.

Blast injury is a complex cause of trauma because it commonly includes both blunt and penetrating trauma, and may also be accompanied by a burn injury.

Several classifications are used to describe the severity and the features of a traumatic injury. The most common is the AAST (American Association for the Surgery of Trauma) injury scoring scale, which is widely used in renal trauma (see the relevant section) (17). For the other urological organs, general practice is that injuries are described by their anatomical site and severity (partial/complete), therefore the elaborated AAST tables were omitted from these guidelines.

1.2.3 **Initial evaluation and treatment**

The initial emergency assessment of the trauma patient is beyond the focus of these guidelines, and is usually carried out by emergency medicine and trauma specialised personnel. The first priority is stabilisation of the patient and treatment of associated life-threatening injuries. The initial treatment should include securing the airway, controlling external bleeding and resuscitation of shock. In many cases, physical examination is carried out during the stabilisation of the patient.

A direct history is obtained from conscious patients. Witnesses and emergency personnel can provide valuable information about unconscious or seriously injured patients. In penetrating injuries, important information includes the size of the weapon in stabbings, and the type and calibre of the weapon used in gunshot wounds. The medical history should be as detailed as possible, as pre-existing organ dysfunction can have a negative effect on trauma patient outcome (18,19).

It is essential that all persons treating trauma patients are aware of the risk of hepatitis B and C infection. An infection rate of 38% was reported among males with penetrating wounds to the external genitalia (20). In any penetrating trauma, tetanus vaccination should be considered according to the patient's vaccination history and the features of the wound itself (CDC tetanus wound management) (21).

1.3 **References**

1. Produced by Bob Phillips, Chris Ball, Dave Sackett, Doug Badenoch, Sharon Straus, Brian Haynes, Martin Dawes since November 1998. Updated by Jeremy Howick March 2009.
<http://www.cebm.net/index.aspx?o=1025> [Accessed February 2014]
2. Atkins D, Best D, Briss PA, et al; GRADE Working Group. Grading quality of evidence and strength of recommendations. *BMJ* 2004 Jun;328(7454):1490.
<http://www.ncbi.nlm.nih.gov/pubmed/15205295>
3. Guyatt GH, Oxman AD, Vist GE, et al. GRADE: an emerging consensus on rating quality of evidence and strength of recommendations. *BMJ* 2008;336(7650):924-6.
<http://www.ncbi.nlm.nih.gov/pubmed/18436948>
4. Guyatt GH, Oxman AD, Kunz R, et al; GRADE Working Group. Going from evidence to recommendations. *BMJ* 2008 May;336(7652):1049-51.
<http://www.ncbi.nlm.nih.gov/pmc/articles/PMC2376019/?tool=pubmed>
http://www.gradeworkinggroup.org/publications/Grading_evidence_and_recommendations_BMJ.pdf
5. Summerton DJ, Kitrey ND, Lumen N, et al. EAU guidelines on iatrogenic trauma. *Eur Urol* 2012 Oct;62(4):628-39.
<http://www.ncbi.nlm.nih.gov/pubmed/22717550>
6. Martínez-Piñero L, Djakovic N, Plas E, et al; European Association of Urology EAU Guidelines on Urethral Trauma. *Eur Urol* 2010 May;57(5):791-803
<http://www.ncbi.nlm.nih.gov/pubmed/20122789>
7. Søreide K. Epidemiology of major trauma. *Br J Surg* 2009 Jul;96(7):697-8.
<http://www.ncbi.nlm.nih.gov/pubmed/19526611>
8. Middleton P. The trauma epidemic. In Jason Smith, Ian Greaves, Keith (2010). *Major trauma* (1. publ. ed.). Oxford: Oxford University Press. p. 2. ISBN 978-0-19-954332-8.
9. Baverstock, R, Simons, R, McLoughlin, M. Severe blunt renal trauma: a 7-year retrospective review from a provincial trauma centre. *Can J Urol* 2001 Oct;8(5):1372-6.
<http://www.ncbi.nlm.nih.gov/pubmed/11718633>
10. Meng MV, Brandes SB, McAninch JW. Renal trauma: indications and techniques for surgical exploration. *World J Urol* 1999 Apr;17(2):71-7.
<http://www.ncbi.nlm.nih.gov/pubmed/10367364>

11. Bruce LM, Croce MA, Santaniello JM, et al. Blunt renal artery injury: incidence, diagnosis, and management. *Am Surg* 2001 Jun;67(6):550-4;discussion 555-6.
<http://www.ncbi.nlm.nih.gov/pubmed/11409803>
12. Kuan JK, Kaufman R, Wright JL, et al. Renal injury mechanisms of motor vehicle collisions: analysis of the crash injury research and engineering network data set. *J Urol* 2007 Sep;178(3Pt1):935-40; discussion 940.
<http://www.ncbi.nlm.nih.gov/pubmed/17632156>
13. Pereira BM, Ogilvie MP, Gomez-Rodriguez JC, et al. A review of ureteral injuries after external trauma. *Scand J Trauma Resusc Emerg Med* 2010 Feb;18:6.
<http://www.ncbi.nlm.nih.gov/pubmed/20128905>
14. Bjurlin MA, Fantus RJ, Mellett MM, et al. Genitourinary injuries in pelvic fracture morbidity and mortality using the National Trauma Data Bank. *J Trauma* 2009 Nov;67(5):1033-9.
<http://www.ncbi.nlm.nih.gov/pubmed/19901665>
15. Dixon CM. Diagnosis and acute management of posterior urethral disruptions, In: McAninch JW (ed). *Traumatic and reconstructive urology*. Philadelphia: WB Saunders, 1996, pp. 347-355.
16. Brandes SB, Buckman RF, Chelsky MJ, et al. External genitalia gunshot wounds: a ten-year experience with fifty-six cases. *J Trauma* 1995 Aug;39(2):266-71.
<http://www.ncbi.nlm.nih.gov/pubmed/7674395>
17. Moore EE, Shackford SR, Pachter HL, et al. Organ injury scaling: spleen, liver, and kidney. *J Trauma* 1989 Dec;29(12):1664-6.
<http://www.ncbi.nlm.nih.gov/pubmed/2593197>
18. Wutzler S, Maegele M, Marzi I, et al. Association of preexisting medical conditions with in-hospital mortality in multiple-trauma patients. *J Am Coll Surg* 2009 Jul;209(1):75-81.
<http://www.ncbi.nlm.nih.gov/pubmed/19651066>
19. Shoko T, Shiraishi A, Kaji M, et al. Effect of pre-existing medical conditions on in-hospital mortality: analysis of 20,257 trauma patients in Japan. *J Am Coll Surg* 2010 Sep;211(3):338-46.
<http://www.ncbi.nlm.nih.gov/pubmed/20800190>
20. Cline KJ, Mata JA, Venable DD, et al. Penetrating trauma to the male external genitalia. *J Trauma* 1998 Mar;44(3):492-4.
<http://www.ncbi.nlm.nih.gov/pubmed/9529176>
21. CDC. Tetanus wound management. Available at:
<http://www.cdc.gov/vaccines/pubs/pinkbook/downloads/tetanus.pdf>

2. RENAL TRAUMA

2.1 Introduction

The incidence of urological tract injury following abdominal trauma is approximately 10%. Renal trauma occurs in approximately 1-5% of all trauma cases (1). The kidney is the most commonly injured genitourinary organ in all ages with the male-to-female ratio being 3:1 (2,3). During the past 20 years, advances in imaging and treatment strategies have increased the ability to achieve renal preservation and decreased the need for surgical intervention. Most injuries are now managed conservatively (4).

2.2 Mode of injury

Renal injuries are classified by their mechanism as blunt or penetrating. In rural settings, blunt trauma comprises the largest percentage of injuries at 90-95%, whereas in urban settings penetrating injuries comprise 40% (5).

2.2.1 *Blunt renal injuries*

Mechanisms include motor vehicle collision, falls, vehicle-associated pedestrian accidents, sports and assault.

Traffic accidents cause almost half of all blunt injuries (6). In a frontal impact, renal injuries may be caused by acceleration of the occupant(s) into the seat belt or steering wheel. In a side impact, injuries occur when the vehicle side panel intrudes into the compartment and hits the occupant (7). Frontal and side airbags reduce the risk of renal injury by 45.3% and 52.8%, respectively (8). Sudden deceleration or a crash injury may result in contusion and laceration of the parenchyma. A 20-year review of renal injuries following free falls found a rate of 16% (9).

A direct blow to the flank or abdomen during sports activities is another cause of blunt injury. Renal vascular injuries generally occur in < 5% of blunt abdominal trauma; isolated renal artery injury is very rare (0.05-0.08%) (10).

Renal artery occlusion is associated with rapid deceleration injuries. In theory, the mechanism is arterial traction. The resulting tear in the inelastic intima and subsequent haemorrhage into the vessel wall leads to thrombosis. Compression of the artery between the anterior abdominal wall and the vertebral bodies may result in vessel thrombosis.

2.2.2 Penetrating renal injuries

Gunshot and stab wounds are the most common causes of penetrating injuries and tend to be more severe and less predictable than those from blunt trauma. Bullets have a higher kinetic energy than knives and so have the potential to cause greater parenchymal destruction and are most often associated with multiple-organ injuries (11). Penetrating injury produces direct tissue disruption of the parenchyma, vascular pedicles, or collecting system.

2.2.3 Injury classification

The most commonly used system is that of the American Association for the Surgery of Trauma (AAST) (12) (Table 2.1). Abdominal computed tomography (CT) or direct exploration is used to classify injuries. This validated system has clinical and prognostic relevance. It helps to predict the need for intervention (13), morbidity after blunt or penetrating injury, and mortality after blunt injury (14).

Table 2.1: AAST renal injury grading scale

| Grade* | Description of injury |
|--------|--|
| 1 | Contusion or non-expanding subcapsular haematoma No laceration |
| 2 | Non-expanding peri-renal haematoma Cortical laceration < 1 cm deep without extravasation |
| 3 | Cortical laceration > 1 cm without urinary extravasation |
| 4 | Laceration: through corticomedullary junction into collecting system Or Vascular: segmental renal artery or vein injury with contained haematoma, or partial vessel laceration, or vessel thrombosis |
| 5 | Laceration: shattered kidney Or Vascular: renal pedicle or avulsion |

*Advance one grade for bilateral injuries up to grade III.

Proposals for changes to the AAST renal injury grading scale include:

- Substratification of the intermediate-grade injury into grade 4a (low-risk cases are likely to be managed non-operatively) and grade 4b (high-risk cases are likely to benefit from angiographic embolization, repair or nephrectomy), based on the presence or absence of important radiographic risk factors, including peri-renal haematoma, intravascular contrast extravasation, and laceration complexity (15);
- Grade 4 injuries should comprise all collecting system injuries, including ureteropelvic junction (UPJ) injury of any severity and segmental arterial and venous injuries;
- According to the last proposal, grade 5 injuries should include only hilar injuries, including thrombotic events (16).

2.3 Diagnosis

When renal injury is suspected during clinical examination, further evaluation is required.

2.3.1 Patient history and physical examination

Possible indicators of major renal injury include a rapid deceleration event (fall, high-speed motor vehicle accidents) or a direct blow to the flank. In assessing trauma patients after motor vehicle accidents, the history should include the vehicle's speed and whether the patient was a passenger or pedestrian.

In the early resuscitation phase, special consideration should be given to pre-existing renal disease (17). In patients with a solitary kidney, who are injured, the whole functioning renal mass might be endangered (18). Pre-existing abnormality makes renal injury more likely following trauma. Pre-existing pathology should be noted. Hydronephrosis due to ureteropelvic junction abnormality, calculi, cysts and tumours are the most commonly reported conditions that may complicate a minor injury (18). The overall percentage of these cases varies from 4% to 22% (19).

Haemodynamic stability is the most important factor in the management of renal injury. Vital signs

should be recorded throughout diagnostic evaluation. Physical examination may reveal an stab or bullet (entry or exit) wound to the back, flank or abdomen. In stab wounds, the extent of the entrance wound may not accurately reflect the depth of penetration.

Blunt trauma to the back, flank, lower thorax or upper abdomen may result in renal injury. Haematuria, flank pain, ecchymoses, abrasions, fractured ribs, abdominal distension and/or mass and tenderness raise the suspicion of renal involvement.

2.3.1.1 Recommendations

| | GR |
|---|----|
| Haemodynamic stability should be assessed upon admission. | A* |
| History should be taken from conscious patients, witnesses and rescue team personnel with regard to the time and setting of the incident. | A* |
| Past renal surgery, and known pre-existing renal abnormalities (ureteropelvic junction obstruction, large cysts, lithiasis) should be recorded. | A* |
| A thorough examination should be made of the thorax, abdomen, flanks and back for penetrating wounds. | A* |
| Findings on physical examination, such as haematuria, flank pain, flank abrasions and bruising ecchymoses, fractured ribs, abdominal tenderness, distension or mass, could indicate possible renal involvement. | A* |

*Upgraded panel consensus.

GR = grade of recommendation.

2.3.2 Laboratory evaluation

Urinalysis, haematocrit and baseline creatinine are the most important tests for evaluating renal trauma. Haematuria, either microscopic or gross, is often seen, but it is neither sensitive nor specific enough to differentiate between minor and major injuries (20).

Major injury, such as disruption of the UPJ, pedicle injuries and segmental arterial thrombosis in approximately 9% of patients with stab wounds and renal injury may occur without haematuria (21). Haematuria that is out of proportion to the history of trauma may suggest pre-existing renal pathology (22). A urine dipstick is an acceptably reliable and rapid test to evaluate haematuria. However, some studies have shown false-negative rates ranging from 3-10% using the dipstick test (23).

Serial haematocrit determination, together with vital signs, is used for continuous evaluation of the trauma patient. A decrease in haematocrit and the requirement for blood transfusions are indirect signs of the rate of blood loss and, together with the patient's response to resuscitation, are valuable in the decision-making process.

As most trauma patients are evaluated within 1 hour of injury, creatinine measurement reflects renal function prior to the injury. An increased creatinine level usually reflects pre-existing renal pathology. Animal models have shown that serum creatinine levels remain in the normal range 8 hours after bilateral nephrectomy (24).

2.3.2.1 Recommendations

| | GR |
|--|----|
| Urine from a patient with suspected renal injury should be inspected for haematuria (visually and by dipstick analysis). | A |
| Creatinine levels should be measured to identify patients with impaired renal function prior to injury. | C |

GR = grade of recommendation.

2.3.3 Imaging: criteria for radiographic assessment

Decisions about radiographic imaging in cases of suspected renal trauma are based on clinical findings and the mechanism of injury. Since most renal injuries are not significant and resolve without any intervention, many attempts have been made to identify which patients could be spared the discomfort, radiation exposure, possible allergic reaction, time and expense of a radiographic evaluation (25).

Indications for radiographic evaluation are gross haematuria, microscopic haematuria with hypotension, or the presence of major associated injuries. However, patients with a history of rapid deceleration injury, clinical indicators of renal trauma or associated injuries need immediate imaging to rule out ureteral avulsion or pedicle injury, with non-visible haematuria without shock after blunt trauma having a low likelihood of concealing significant injury (26).

Patients with penetrating trauma to the torso have a high incidence of significant renal injuries. If there is a suspicion on the basis of an entry or exit wound, imaging should be performed, regardless of the degree of haematuria (27).

2.3.3.1 *Ultrasound (US)*

Ultrasound provides a quick, non-invasive, low-cost means of detecting peritoneal fluid collections without exposure to radiation (28). Focused assessment with sonography for trauma (FAST) rapidly assesses for haemoperitoneum and haemopericardium. The results are both highly operator- and patient-dependent. Ultrasound scans can detect lacerations, but cannot accurately assess their depth and extent. They do not provide functional information about excretion or urine leakage. Ultrasound is useful for the routine follow-up of parenchymal lesions or haematomas in the intensive care unit and for serially evaluating stable injuries for the resolution of urinomas and retroperitoneal haematomas (20).

Since US scans are used in the triage of patients with blunt abdominal trauma in many centres, they can help to identify which patients require a more detailed radiological investigation (29). Contrast-enhanced US is described as more sensitive than conventional US in the detection of renal injuries, but it is not commonly used. In haemodynamically stable patients, it is a useful tool for assessing blunt injuries (30).

2.3.3.2 *Intravenous pyelography (IVP)*

Although IVP is a sensitive modality, it has largely been replaced by CT scanning (31). The use of IVP is recommended when it is the only modality available (32). IVP can be used to establish the presence or absence of one or both kidneys, clearly define the parenchyma, and outline the collecting system. The most significant findings are non-function and extravasation. Non-function is a sign of extensive trauma to the kidney, pedicle injury (vascular avulsion or thrombosis), or a severely shattered kidney. Extravasation of the contrast medium also implies a severe degree of trauma, involving the capsule, parenchyma and collecting system. Other less reliable signs are delayed excretion, incomplete filling, caliceal distortion and obscuring of the renal shadow. Non-visualization, contour deformity or contrast extravasation should prompt further radiological evaluation. The sensitivity of IVP is high (> 92%) for all degrees of trauma severity.

2.3.3.3 *One-shot intra-operative IVP*

In unstable patients, undergoing emergency laparotomy, a one-shot IVP may provide information on the presence of a normal, functioning, contralateral kidney (33). The technique consists of a bolus intravenous injection of 2 mL/kg of radiographic contrast followed by a single plain film taken after 10 minutes. The study is safe, efficient and high quality in most cases (34).

2.3.3.4 *Computed tomography (CT)*

CT is the best method for assessment of stable patients with renal trauma. CT is more sensitive and specific than IVP, US or angiography, since it accurately defines the location of injuries, easily detects contusions and devitalized segments, visualizes the entire retroperitoneum and any associated haematomas, and includes other abdominal and pelvic structures. It demonstrates superior anatomical details, including the depth and location of lacerations and the presence of associated abdominal injuries, and establishes the presence and location of the contralateral kidney. CT is particularly useful in evaluating traumatic injuries to kidneys with pre-existing abnormalities (35).

Intravenous contrast should be administered for renal evaluation. **A lack of contrast enhancement of the injured kidney is a hallmark of pedicle injury.** In cases where this typical finding is not demonstrated, central parahilar haematoma increases the possibility of pedicle injury; this sign should be considered even if the parenchyma is well enhanced (36). Renal vein injury remains difficult to diagnose with any type of radiographic study, but the presence on CT of a large haematoma, medial to the kidney and displacing the vasculature, should raise the suspicion of venous injury.

Spiral CT provides a shorter scanning time and thus fewer artifacts in the examinations of patients who cannot co-operate adequately (37). Three-dimensional post-processing modalities allow assessment of the vascular pedicle by CT angiography and improve the demonstration of complex lacerations of the parenchyma (38). **However, injury to the collecting system may be missed during routine spiral CT. In all cases of suspected trauma evaluated with spiral CT, repeat kidney scans should be performed 10-15 minutes after contrast injection** (39). Most blunt ureteral and UPJ injuries can be identified if delayed excretory CT scans are performed (40). CT scanning is an essential diagnostic procedure in patients with gunshot wounds who are being considered for non-operative management (41). Missed injuries are common but minor and do not alter the patients' clinical course (42).

2.3.3.5 Magnetic resonance imaging (MRI)

Although MRI is sensitive in the evaluation of blunt trauma (43), it is not the first imaging choice in patients with trauma because it requires a longer imaging time and patient access is limited during MRI. It is useful in renal trauma only if CT is not available, in patients with iodine allergy, or in the very few cases for which CT findings are equivocal (44).

2.3.3.6 Angiography

Angiography is indicated mainly for stable patients who are candidates for radiological control of haemorrhage defined on CT (45). Although angiography is less specific, more time-consuming and more invasive than CT, it is more specific for defining the exact location and degree of vascular injuries. It is indicated in the management of persistent or delayed management of haemorrhage from branching vessels (35). Angiography can define lacerations, extravasation and pedicle injury. It is also the test of choice for evaluating venous injuries. Another indication is non-enhancement of the cortex on CT scan caused by total avulsion of the vessels, renal artery thrombosis and severe contusion causing major vascular spasm.

2.3.3.7 Radionuclide scans

Radionuclide scans are generally used or required only in trauma patients with an allergy to iodinated contrast material (35).

2.3.3.8 Recommendations

| | GR |
|--|----|
| Blunt trauma patients with visible (gross) or non-visible haematuria and haemodynamic instability should undergo radiographic evaluation. | A* |
| Immediate imaging is recommended for all patients with a history of rapid deceleration injury and/or significant associated injuries. | B |
| All patients with or without haematuria after penetrating abdominal or lower thoracic injury require urgent renal imaging. | A* |
| Ultrasound alone should not be used to set the diagnosis of renal injury since it cannot provide sufficient information. However, it can be informative during the primary evaluation of polytrauma patients and for the follow-up of recuperating patients. | C |
| A CT scan with enhancement of intravenous contrast material and delayed images is the gold standard for the diagnosis and staging of renal injuries in haemodynamically stable patients. | A |

*Upgraded following panel consensus.

GR = grade of recommendation.

Consider delayed films on CT to establish if there is contrast leakage - may need stenting.

Consider transfer of Grade IV/V injuries - especially Paediatric cases (Transfer to Leicester)

2.4 Treatment

2.4.1 Indications for renal exploration

The need for renal exploration can be predicted considering the type of injury, transfusion requirements, blood urea nitrogen (BUN) and creatinine levels, and injury grade (46). However, the management of renal injury may be influenced by the decision to explore or observe associated abdominal injuries (47).

Continuing haemodynamic instability, which is unresponsive to aggressive resuscitation due to renal haemorrhage, is an indication for exploration, irrespective of the mode of injury (48). Other indications include an expanding or pulsatile perirenal haematoma, which has been identified at exploratory laparotomy performed for associated injuries. Persistent extravasation or urinoma are usually managed successfully with endourological techniques. Inconclusive imaging and a pre-existing abnormality or an incidentally diagnosed tumour could require surgery, even after relatively minor renal injury (22).

Previously, grade 5 vascular injuries have been regarded as an absolute indication for exploration. However, an increasing number of reports suggest that parenchymal grade 5 patients, who are haemodynamically stable at presentation, might be safely treated conservatively (49). In these patients, intervention is predicted by the need for continued fluid and blood resuscitation. Other factors that increase the risk of surgical intervention are peri-renal haematoma size > 3.5 cm, presence of intravascular contrast extravasation and presence of grade 4-5 injuries (15). Injury Severity Score (ISS) 16 and grade 4 injury are predictive factors for an operation, while higher injury severity (ISS > 16) and lower consciousness level (GCS < 8) are significantly associated with mortality (50).

2.4.2 Interventional radiology

Interventional radiology provides the most important advance in renal trauma management in the last decade. Decisions regarding major lacerations must balance the increased incidence of nephrectomy in patients

undergoing immediate versus delayed surgical exploration, with the increased morbidity of patients who are managed expectantly. Endovascular treatment is an important and less invasive option for managing renovascular trauma that may allow for maximum tissue/organ preservation.

Angiography with selective embolization is a reasonable alternative to laparotomy provided that there is no other indication for immediate open surgery. Haemodynamically stable patients with grade 3 injuries or higher should be considered for formal angiography followed by embolization if active bleeding is noticed (51).

Angiography is indicated by positive radiological findings, including massive extravasation, presence of a large devascularized segment or identification of grade 4/5 lesions, arterial laceration, avulsion, global or segmental hypoperfusion of kidney, intimal tear or false aneurysm, segmental or subsegmental arterial bleeding, or thrombosis.

Peri-renal haematoma size compressing the kidney and impairing perfusion (peri-nephric compartment syndrome or 'page kidney') and intravascular contrast extravasation are also readily detectable radiographic features, associated with the need for embolization (52).

Some polytrauma patients will undergo laparotomy and open repair of intra-peritoneal organ injuries, but then undergo angio-embolization of renal injuries identified on CT or suspected by an expanding retroperitoneal haematoma at the time of surgery. Angio-embolization also has a role in patients with persistent post-traumatic haematuria. Since the success rate is equally high for initial and repeat interventions, re-intervention is justified when the clinical course allows (53).

The most common injury to the main renal artery is dissection, usually with partial or complete occlusion. Complete arterial avulsion is less common. The management of artery occlusion remains controversial. Arterial bleeding may spontaneously cease when tamponade develops within Gerota's fascia. However, when the fascia has been violated, tamponade will be lost and the haematoma will extend to the pararenal space.

Without transcatheter embolization, attempts to stabilize such patients are unlikely to be successful so that the only option is emergency laparotomy (54). The reported clinical success rate of renal embolization for trauma is 65%, but angiography has a success rate of 94.45% for blunt injuries in stable patients (55). Cure of haematuria after superselective transarterial embolization is reported as high as 98%, which is similar for both blunt and penetrating injuries (56). The complication rate is minimal. Although it has been proven effective for grade 4 injuries initially selected for conservative therapy, it failed when applied to grade 5 injuries (55).

Renal pedicle injuries are normally managed surgically, but there are increasing reports of endovascular treatment options for traumatic arterial dissections and ruptures. In specific clinical circumstances, such as severe polytrauma or a patient with high operative risk, the main artery may be embolized, either as a definitive treatment or to be followed by interval nephrectomy after the patient's clinical condition has improved (57). The angiographic findings in more peripheral artery injuries include contrast extravasation, pseudoaneurysm, arterial transection, arterial wall irregularity, arteriovenous fistulas (AVFs) and arterio-caliceal fistula.

Angio-embolization for grade 4-5 injuries should be done with caution since the initial success rate is low and usually requires additional procedures. However, the procedure itself is safe and not associated with intermediate-term adverse events (58). Such patients, who have no other indications for immediate abdominal surgery, benefit from arteriography and possible embolization. The additional contrast agent needed for arteriography does not increase the incidence of nephropathy (59).

2.4.3 **Operative findings and reconstruction**

The overall exploration rate for blunt trauma is less than 10% (60), and may be even lower as more centres adopt a conservative approach to management of these patients (61). The goal of exploration following renal trauma is control of haemorrhage and renal salvage. Most large series suggest the transperitoneal approach for surgery (62). Access to the pedicle is obtained either through the posterior parietal peritoneum, which is incised over the aorta, just medial to the inferior mesenteric vein, or by bluntly dissecting along the plane of the psoas muscle fascia adjacent to the great vessels and directly placing a vascular clamp on the hilum (63). Stable haematomas detected during exploration for associated injuries should not be opened. Central or expanding haematomas indicate injuries of the renal pedicle, aorta, or vena cava and are potentially life-threatening (64).

In cases with unilateral arterial intimal disruption, repair can be delayed, especially in the presence of a normal contralateral kidney, but prolonged warm ischemia usually results in irreparable damage and renal loss. Entering the retroperitoneum and leaving the confined haematoma undisturbed within the perinephric fascia is recommended unless it is violated and cortical bleeding is noted; temporarily packing the fossa tightly with laparotomy pads can salvage the kidney (65). Haemorrhage can occur while the patient is resuscitated, warmed, and awaits re-exploration but careful monitoring is sufficient. A brief period of controlled local urinary extravasation is unlikely to result in a significant adverse event or impact overall recovery. At the next 48-72 hours, CT scans can identify injuries and select patients for reconstruction or continued expectant management (66). Ureteral stenting or nephrostomy diversion should be strongly considered after delayed

reconstruction because of the increased risk of post-operative urinary extravasation.

Renal reconstruction is feasible in most cases. The overall rate of patients who have a nephrectomy during exploration is around 13%, usually in patients with penetrating injury and higher rates of transfusion requirements, haemodynamic instability, and higher injury severity scores (67). Other intra-abdominal injuries also slightly increase the need for nephrectomy (68). Mortality is associated with the overall severity of the injury and is not often a consequence of the renal injury itself (69). In gunshot injuries caused by a high-velocity bullet, reconstruction can be difficult and nephrectomy is often required (70). Renorrhaphy is the most common reconstructive technique. Partial nephrectomy is required when non-viable tissue is detected. Watertight closure of the collecting system, if open, is desirable, although some experts merely close the parenchyma over the injured collecting system with good results. If the capsule is not preserved, an omental pedicle flap or perirenal fat bolster may be used for coverage (71). The use of haemostatic agents and sealants in reconstruction can be helpful (72). In all cases, drainage of the ipsilateral retroperitoneum is recommended to provide an outlet for any temporary leakage of urine.

Following blunt trauma, repair of vascular injuries (grade 5) is seldom, if ever, effective (73). Repair should be attempted in patients with a solitary kidney or bilateral injuries (74) but is not used in the presence of a functioning contralateral kidney (75). Nephrectomy for main artery injury has outcomes similar to those of vascular repair. It does not worsen post-treatment renal function in the short term.

2.4.4 Non-operative management of renal injuries

2.4.4.1 Blunt renal injuries

Non-operative management has become the treatment of choice for most renal injuries. In stable patients, this means supportive care with bed-rest and observation. Primary conservative management is associated with a lower rate of nephrectomy, without any increase in the immediate or long-term morbidity (76).

Hospitalization or prolonged observation for evaluation of possible injury after a normal abdominal CT scan, when combined with clinical judgment, is unnecessary in most cases (77). All grade 1 and 2 injuries can be managed non-operatively, whether due to blunt or penetrating trauma. The treatment of grade 3 injuries has been controversial, but recent studies support expectant treatment (78).

Most patients with grade 4 and 5 injuries present with major associated injuries, and consequently experience high exploration and nephrectomy rates (79), although emerging data indicate that many of these patients can be managed safely with an expectant approach (80). An initially conservative approach is feasible in stable patients with devitalized fragments (81), although these injuries are associated with an increased rate of complications and late surgery (82). Patients diagnosed with urinary extravasation in solitary injuries can be managed without major intervention and a resolution rate of > 90% (83). Unilateral main arterial injuries will normally be managed non-operatively in a haemodynamically stable patient, with surgical repair reserved for bilateral artery injuries or injuries involving a solitary functional kidney. Conservative management is advised in the treatment of unilateral complete blunt artery thrombosis. These patients need close follow-up because of the risk of hypertension. Blunt artery thrombosis in multiple trauma patients indicates severe injury; attempts at repair are usually unsuccessful (84).

2.4.4.2 Penetrating renal injuries

Penetrating wounds have traditionally been approached surgically. However, a systematic approach based on clinical, laboratory and radiological evaluation minimizes negative exploration without increasing morbidity from a missed injury (48). Selective non-operative management of abdominal stab wounds is generally accepted by an increasing proportion of trauma centres (85).

Persistent bleeding represents the main indication for exploration and reconstruction. In all cases of severe injury, non-operative management should occur only after complete renal staging in haemodynamically stable patients (86).

Isolated grade 4 injuries represent a unique situation to treat the patient based solely on the extent of the renal injury. Gunshot injuries should be explored only if they involve the hilum or are accompanied by signs of continued bleeding, ureteral injuries, or renal pelvis lacerations (87). Low-velocity gunshot and minor stab wounds may be managed conservatively with an acceptably good outcome (88). In contrast, tissue damage from high-velocity gunshot injuries can be more extensive and nephrectomy is required more often. Non-operative management of penetrating injuries in selected stable patients is associated with a successful outcome in approximately 50% of stab wounds and up to 40% of gunshot wounds (89-91). If the site of penetration by stab wound is posterior to the anterior axillary line, 88% of such renal injuries can be managed non-operatively (92).

Stab wounds producing major renal injuries (grade 3 or higher) are more unpredictable and are associated with a higher rate of delayed complications if treated expectantly (93).

2.4.5 Recommendations

| | GR |
|---|----|
| Following blunt renal trauma, stable patients should be managed conservatively and closely monitored for vital signs until gross haematuria resolves. | B |
| Isolated grade 1-3 stab and low-velocity gunshot wounds in stable patients, after complete staging, should be managed expectantly. | B |
| Indications for renal exploration include: <ul style="list-style-type: none"> • haemodynamic instability; • exploration for associated injuries; • expanding or pulsatile peri-renal haematoma identified during laparotomy; • grade 5 vascular injury. | B |
| Radiological embolization is indicated in patients with active bleeding from renal injury but without other indications for immediate abdominal operation. | B |
| Intra-operatively, renal reconstruction should be attempted once haemorrhage is controlled and there is sufficient viable renal parenchyma. | B |

GR = grade of recommendation.

2.4.6 Post-operative care and follow-up

The risk of complications in patients who have been treated conservatively increases with grade. Repeat imaging 2-4 days after trauma minimizes the risk of missed complications, especially in grade 3-5 blunt injuries (94). However, the usefulness of frequent CT scanning after injury has never been satisfactorily proven and its use should be weighed against the risk of increased radiation exposure. CT scans should always be performed on patients with fever, unexplained decreasing haematocrit or significant flank pain. Repeat imaging can be safely omitted for patients with grade 1-4 injuries as long as they remain clinically well (95).

Nuclear scans are useful for documenting and tracking functional recovery in patients following renal reconstruction (96). Follow-up should involve physical examination, urinalysis, individualized radiological investigation, serial blood pressure measurement and serum determination of renal function (81). A decline in renal function directly correlates with AAST injury grade; this is independent of the mechanism of injury (blunt vs. penetrating) and the method of management (non-operative vs. repair) (97). Follow-up examinations should continue until healing is documented and laboratory findings have stabilized, although checking for latent renovascular hypertension may need to continue for years (98). The literature is generally inadequate on the subject of the long-term consequences of trauma on renal tissue.

2.4.7 Complications

Early complications, occurring less than 1 month after injury, can be bleeding, infection, perinephric abscess, sepsis, urinary fistula, hypertension, urinary extravasation and urinoma. Delayed complications include bleeding, hydronephrosis, calculus formation, chronic pyelonephritis, hypertension, AVF, hydronephrosis and pseudoaneurysms. Delayed retroperitoneal bleeding may be life-threatening and selective angiographic embolization is the preferred treatment (99). Perinephric abscess formation is usually best managed by percutaneous drainage, although open drainage may sometimes be required. Percutaneous management of complications may pose less risk of renal loss than re-operation, which may lead to nephrectomy when infected tissues make reconstruction difficult (60).

Renal trauma is a rare cause of hypertension, mostly in young men. The frequency of post-traumatic hypertension is estimated to be < 5% in all published series (100,101). Hypertension may occur acutely as a result of external compression from perirenal haematoma (Page kidney), or chronically because of compressive scar formation. Hypertension is usually renin-dependent and associated with parenchymal injury. Renin-mediated hypertension may occur as a long-term complication; aetiologies include renal artery thrombosis, segmental arterial thrombosis, renal artery stenosis (Goldblatt kidney), devitalized fragments and AVFs. Arteriography is informative in cases of post-traumatic hypertension. Treatment is required if the hypertension persists and could include medical management, excision of the ischaemic parenchymal segment, vascular reconstruction, or total nephrectomy (102).

Urinary extravasation after reconstruction often subsides without intervention as long as ureteral obstruction and infection are not present. Ureteral retrograde stenting may improve drainage and allow healing (103). Persistent urinary extravasation from an otherwise viable kidney after blunt trauma often responds to stent placement and/or percutaneous drainage as necessary (104).

Arteriovenous fistulae usually present with delayed onset of significant haematuria, most often after penetrating trauma. Percutaneous embolization is often effective for symptomatic AVFs, but larger ones may require surgery (105). Post-procedural complications include infection, sepsis, urinary fistula, and

renal infarction (106). The development of pseudoaneurysm is a rare complication following blunt trauma. In numerous case reports, transcatheter embolization appears to be a reliable minimally invasive solution (107). Acute renal colic from a retained missile has been reported, and can be managed endoscopically if possible (108). Other unusual late complications, such as duodenal obstruction, may result from retroperitoneal haematoma following blunt trauma (109).

2.4.8 Recommendations

| | GR |
|---|----|
| Repeat imaging is recommended in cases of fever, flank pain, or falling haematocrit. | B |
| Nuclear scintigraphy is useful for documenting functional recovery. | C |
| First follow-up should be at approximately 3 months after major renal injury with hospitalization. Each follow-up should include: physical examination, urinalysis, individualized radiological investigation, serial blood pressure measurement and renal function test. | C |
| Medical management and minimally invasive techniques should be the first choice for the management of complications. | C |
| Long-term follow-up should be decided on a case-by-case basis. | C |

GR = grade of recommendation.

2.4.9 Renal injury in the polytrauma patient

Approximately 8-10% of blunt and penetrating abdominal injuries involve the kidneys. The incidence of associated injury in penetrating renal trauma ranges from 77-100%. Gunshot wounds are associated with organ injury more often than stab wounds. Most patients with penetrating renal trauma have associated adjacent organ injuries that may complicate treatment. In the absence of an expanding haematoma with haemodynamic instability, associated multiorgan injuries do not increase the risk of nephrectomy (5). Blunt and penetrating trauma contributed equally to combined renal and pancreatic injury. Renal preservation was achieved in most patients, and the complication rate of the series was 15% (110). A similar rate of complications (16%) was reported in patients with simultaneous colon and renal injury. In a report reviewing this combination of injuries over a period of 17 years, 58% of patients underwent an exploration, with nephrectomies performed in 16% of explorations (111). Renal injuries seem to be rare in patients with blunt chest trauma. In a study of polytrauma patients, conservative management was safely attempted without increasing morbidity (112).

2.4.10 Recommendations

| | GR |
|--|----|
| Polytrauma patients with associated renal injuries should be evaluated on the basis of the most threatening injury. | C |
| In cases where surgical intervention is chosen, all associated abdominal injuries should be managed where appropriate, simultaneously. | C |
| The decision for conservative management should consider all injuries independently. | C |

GR = grade of recommendation.

2.5 Iatrogenic renal injuries

2.5.1 Introduction

Iatrogenic renal trauma is rare but can lead to significant morbidity.

2.5.2 Incidence and aetiology

The commonest causes of iatrogenic renal trauma are listed in Table 2.2 (113).

Table 2.2: Incidence and aetiology of commonest iatrogenic renal trauma during various procedures

| Procedure | Haemorrhage | AVF | Pseudo-aneurysm | Renal pelvis injury | Aortocaliceal fistula | Foreign body |
|---------------------------------|--------------|-----|-----------------|---------------------|-----------------------|--------------|
| Nephrostomy | + | | + | + | | |
| Biopsy | + (0.5-1.5%) | + | + (0.9%) | | | |
| PCNL | + | + | | + | | |
| Laparoscopic surgery (oncology) | + | | | | | |
| Open surgery (oncology) | + | | + (0.43%) | | | + |
| Transplantation | + | + | + | | + | |
| Endopyelotomy | + | | | + | | + |
| Endovascular procedure | + (1.6%) | | | | | |

AVF = arteriovenous fistulae; PCNL = percutaneous nephrolithotomy.

Large haematomas after biopsy (0.5-1.5%) are caused by laceration or arterial damage (114). Renal artery and intraparenchymal pseudoaneurysms (0.9%) may be caused by percutaneous biopsy, nephrostomy, and partial nephrectomy (0.43%) (115). In PCNL, haemorrhage is the most dangerous iatrogenic renal trauma. Vascular injuries are quite common at any stage of the procedure, especially when punctures are too medial or directly penetrate the renal pelvis. Other injuries include AVFs or a tear in the pelvicaliceal system, causing extravasation and absorption of irrigation fluid. Iatrogenic renal traumas in transplantation are more common and include AVFs, intrarenal pseudoaneurysms, arterial dissection and arteriocaliceal fistulas. Pseudoaneurysm is a rare complication of allograft biopsy. Although the overall complication rate with biopsies in transplant kidneys is 9% (including haematoma, AVF, macroscopic haematuria and infection), vascular complications requiring intervention account for 0.2-2.0% (116). Predisposing factors include hypertension, renal medullary disease, central biopsies, and numerous needle passes (117). Arteriovenous fistulas and pseudoaneurysms can occur in 1-18% of allograft biopsies, and may co-exist in up to 30% of cases (114).

Extrarenal pseudoaneurysms after transplantation procedures generally occur at the anastomosis, in association with local or haematogenous infection. Arterial dissection related to transplantation is rare and presents in the early postoperative period (118).

Iatrogenic renal traumas associated with endopyelotomy are classified as major (vascular injury) and minor (urinoma) (119). Patients undergoing cryoablation for small masses via the percutaneous or the laparoscopic approach may have minor iatrogenic renal traumas, including asymptomatic perinephric haematoma and self-limited urine leakage.

Vascular injury is a rare complication (1.6%) of endovascular interventions in contrast to patients with surgical injuries. The renal vessels are vulnerable mainly during oncological procedures (120). Renal foreign bodies, with retained sponges or wires during open or endourological procedures, are uncommon.

2.5.3 **Diagnosis (clinical signs, imaging)**

Haematuria is common after nephrostomy, but massive retroperitoneal haemorrhage is rare. If a nephrostomy catheter appears to transfix the renal pelvis, significant arterial injury is possible. The misplaced catheter should be withdrawn over a guide wire and embolization may arrest the haemorrhage rapidly. Computed tomography (CT) can also successfully guide repositioning of the catheter into the collecting system (121). Haemorrhage can be prevented by avoiding puncture in patients receiving anticoagulation treatment or with coagulopathy, by carefully targeting the calices, and by avoiding medial puncture. Injuries to the renal pelvis are less likely to occur if the dilator is not advanced further than the calix, sheaths are handled with care, especially during advancement around the pelviureteric junction, and kinking of the guide wires is avoided (122). After percutaneous biopsy, AVFs may present with severe hypertension. A pseudoaneurysm should be suspected if the patient presents with flank pain and decreasing haematocrit, even in the absence of haematuria.

During PCNL, acute bleeding may be caused by injury to the anterior or posterior segmental arteries. Late post-operative bleeding may be caused by interlobar and lower-pole arterial lesions, AVFs and post-traumatic aneurysms (123). Duplex US and CT angiography can successfully diagnose vascular injuries. Close observation of irrigation fluid input and output is required to ensure early recognition of extravasation of fluid. Intra-operative evaluation of serum electrolytes, acid-base status, oxygenation, and monitoring of airway pressure are good indicators of this complication, since metabolic acidosis, hyponatraemia, hypokalaemia, peritonitis and ileus may occur.

In arterial dissection related to transplantation, symptoms include anuria and a prolonged dependence on dialysis. Doppler US can demonstrate compromised arterial flow. Dissection can lead to thrombosis of the renal artery and/or vein.

Following angioplasty and stent-graft placement in the renal artery, during which wire or catheters may enter the parenchyma and penetrate through the capsule, possible radiological findings include AVF, pseudoaneurysm, arterial dissection and contrast extravasation. Common symptoms of pseudoaneurysms are flank pain and gross haematuria within 2 or 3 weeks after surgery (124). Transplant AVFs and pseudoaneurysms may be asymptomatic or may cause gross haematuria or hypovolemia due to shunting and 'steal' phenomenon, renal insufficiency, hypertension, and high output cardiac failure. Patients with extrarenal pseudoaneurysms may present with infection/bleeding, swelling, pain and intermittent claudication. Doppler US findings for AVFs include high-velocity, low-resistance, spectral waveforms, with focal areas of disorganized colour flow outside the normal vascular borders, and possibly a dilated vein (125). Pseudoaneurysms appear on US as anechoic cysts, with intracystic flow on colour Doppler.

Potential complications of retained sponges include abscess formation, fistulization to the skin or intestinal tract, and sepsis. Retained sponges may cause pseudotumours or appear as solid masses. Magnetic resonance imaging (MRI) clearly shows the characteristic features (126). Absorbable haemostatic agents may also produce a foreign-body giant cell reaction, but the imaging characteristics are not specific. Retained stents, wires, or fractured cutting wires (due to f.i. a retrograde pyelotomy procedure) may also present as foreign bodies and can serve as a nidus for stone formation (127).

2.5.4 **Management**

Small subcapsular haematomas after nephrostomy resolve spontaneously, while AVFs and pseudoaneurysms after biopsy are best managed by embolization (128).

During PCNL, bleeding can be venous or arterial. In major venous trauma with haemorrhage, patients with concomitant renal insufficiency can be treated without open exploration or angiographic embolization, using a Council-tip balloon catheter (129). When there is profuse bleeding at the end of a PCNL, conservative management is usually effective. The patient should be placed in a supine position, clamping the nephrostomy catheter and forcing diuresis. Superselective embolization is required in less than 1% of cases and has proved effective in more than 90% of cases (130).

Short-term deleterious effects are more pronounced in patients with a solitary kidney, but long-term follow-up shows functional and morphological improvements (131). Termination of PCNL if the renal pelvis is torn or ruptured is a safe choice. Management requires close monitoring, placement of an abdominal or retroperitoneal drain and supportive measures (132). Most surgical venous injuries have partial lacerations that can be managed with techniques, such as venorrhaphy, patch angioplasty with autologous vein, or expanded polytetrafluoroethylene (ePTFE) graft (133). If conservative measures fail in cases of pseudoaneurysm and clinical symptoms, or a relevant decrease in haemoglobin occurs, transarterial embolization should be considered (134). As the success rate is similar for initial and repeat interventions, a repeat intervention is justified when the clinical course allows this (53).

Traditionally, patients with post-operative haemorrhage following intra-abdominal laparoscopic surgery of the kidney require laparotomy. Pseudoaneurysms and AVFs are uncommon after minimally invasive partial nephrectomy, but can lead to significant morbidity. Temporary haemostasis occurs with coagulation and/or tamponade, but later degradation of the clot, connection with the extravascular space, and possible fistulization with the collecting system may develop. Patients typically present with gross haematuria, although they may also experience flank pain, dizziness and fever. Embolization is the reference standard for both diagnosis and treatment in the acute setting, although CT can be used if the symptoms are not severe and/or the diagnosis is ambiguous. Reports have described good preservation of renal function after embolization (135).

Endoluminal management after renal transplantation consists of stabilizing the intimal flap with stent placement. Embolization is the treatment of choice for a symptomatic transplant AVF or enlarging pseudoaneurysm (136). Superselective embolization with a coaxial catheter and metallic coils helps limit the loss of normal functioning graft tissue (137). A success rate of 71-100% has been reported, with alleviation of symptoms in 57-88% of cases. Major infarcts involving more than 30-50% of the allograft and leading to allograft loss have been reported in up to 28.6% of cases in which combined coil embolization and polyvinyl alcohol or Gelfoam were used. If symptoms persist, a second angiogram with a possible repeat embolization is warranted (138). Failure of embolization is associated with a high nephrectomy rate. The long-term outcome depends on the course of the transplant and the amount of contrast medium used during the procedure.

Surgical treatment for AVF consists of partial or total nephrectomy or arterial ligation, which results in loss of part of the transplant or the entire transplant. Surgery has to date been the main approach in the treatment of renal vascular injuries. In patients with retroperitoneal haematoma, AVFs, and haemorrhagic shock, interventional therapy is associated with a lower level of risk than surgery (55). Renal arteriography followed by selective embolization can confirm the injury. In injuries during angioplasty and stent-graft placement, transcatheter embolization is the first choice of treatment (139). The treatment for acute iatrogenic rupture of the main renal artery is balloon tamponade. If this fails, immediate availability of a stent graft is vital (140). The

true nature of lesions caused by foreign bodies is revealed after exploration.

2.5.5 Statements and recommendations

| Statements | LE |
|--|----|
| Iatrogenic renal injuries are procedure-dependent (1.8-15%). | 3 |
| Significant injury requiring intervention is rare. | 3 |
| Most common injuries are vascular. | 3 |
| Renal allografts are more susceptible. | 3 |
| Injuries occurring during surgery are rectified immediately. | 3 |
| Symptoms suggestive of a significant injury require investigation. | 3 |

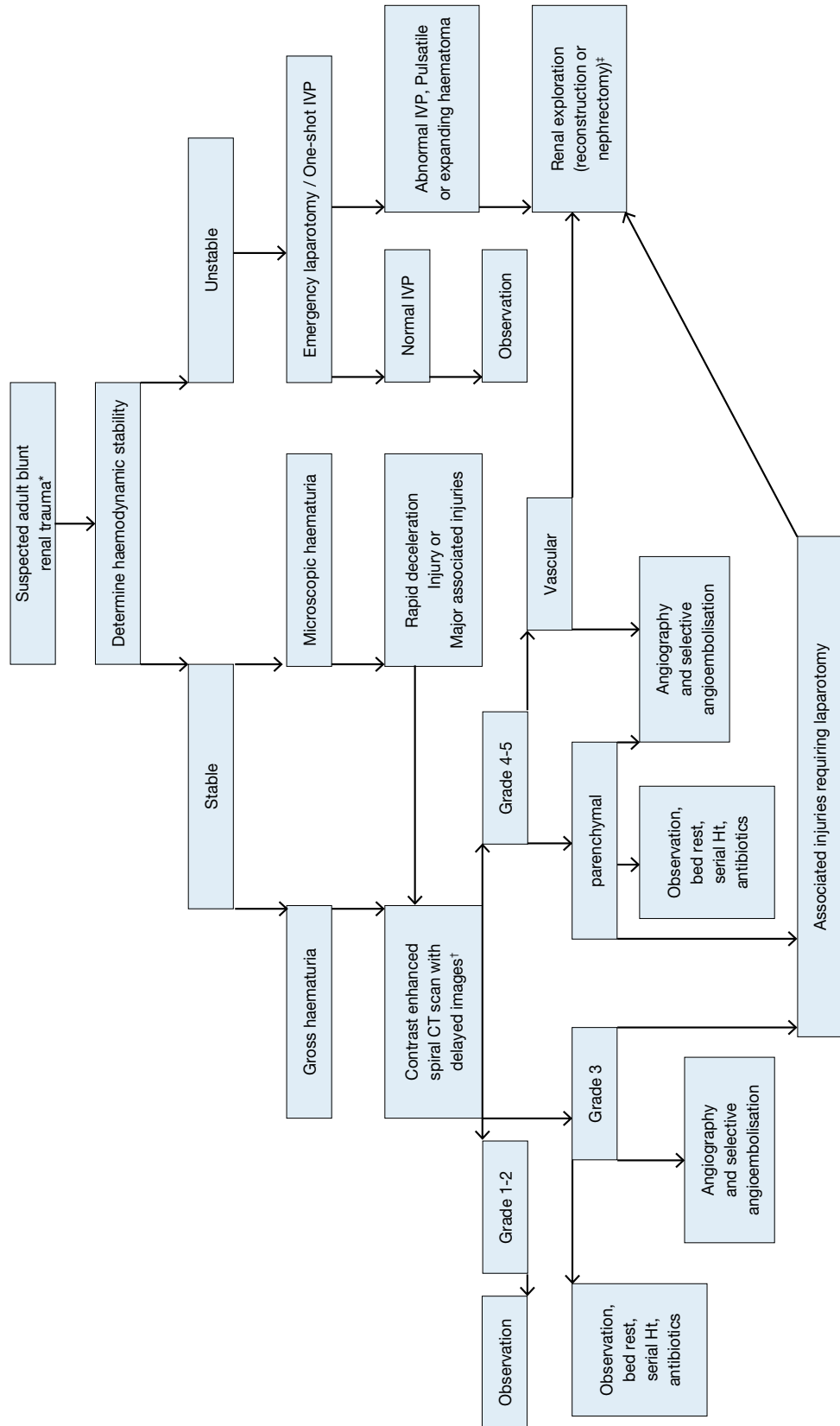
| Recommendations | GR |
|--|----|
| Patients with minor injuries should be treated conservatively. | B |
| Severe or persistent injuries require intervention with embolization. | B |
| In stable patients, a second embolization should be considered in case of failure. | C |

GR = grade of recommendation; LE = level of evidence.

2.6 Algorithms

Figures 2.1 and 2.2 show the suggested treatment of blunt and penetrating renal injuries in adults.

Figure 2.1: Evaluation of blunt renal trauma in adults

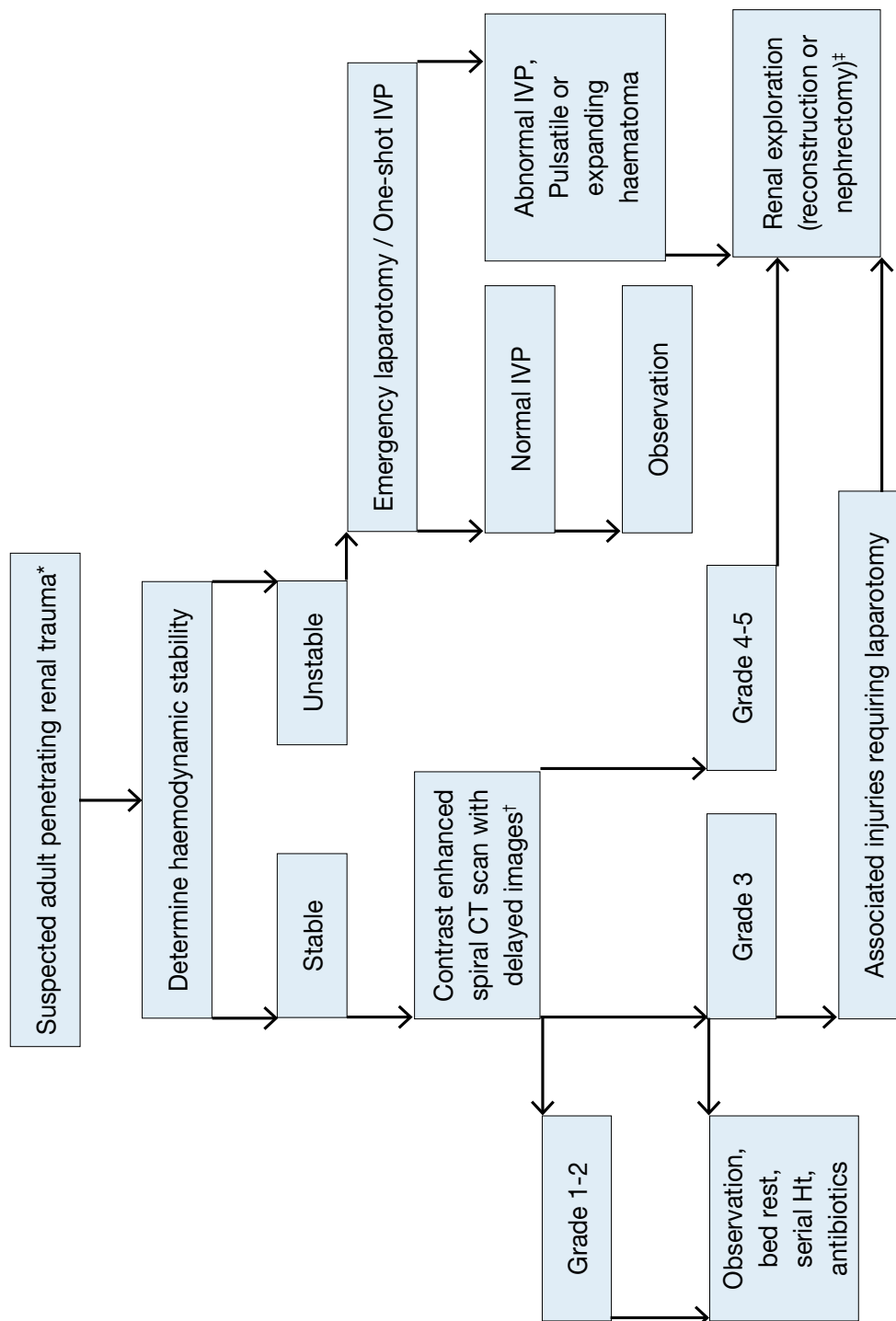


* Suspected renal trauma results from reported mechanism of injury and physical examination.

† Renal imaging: CT scans are the gold standard for evaluating blunt and penetrating renal injuries in stable patients. In settings where the method is not available, the urologist should rely on other imaging modalities (IVP, angiography, radiographic scintigraphy, MRI).

‡ Renal exploration: Although renal salvage is a primary goal for the urologist, decisions concerning the viability of the organ and the type of reconstruction are made during the operation.

Figure 2.2: Evaluation of penetrating renal trauma in adults



* Suspected renal trauma results from reported mechanism of injury and physical examination.

† Renal imaging: CT scans are the gold standard for evaluating blunt and penetrating renal injuries in stable patients. In settings where the method is not available, the urologist should rely on other imaging modalities (IVP, angiography, radiographic scintigraphy, MRI).

‡ Renal exploration: Although renal salvage is a primary goal for the urologist, decisions concerning the viability of the organ and the type of reconstruction are made during the operation.

2.7 References

1. McAninch JW. Genitourinary trauma. World J Urol 1999 Apr;17(2):65. <http://www.ncbi.nlm.nih.gov/pubmed/10367362>
2. Paparel P, N'Diaye A, Laumon B, et al. The epidemiology of trauma of the genitourinary system after traffic accidents: analysis of a register of over 43,000 victims. BJU Int 2006 Feb;97(2):338-41. <http://www.ncbi.nlm.nih.gov/pubmed/16430642>

3. Bjurlin MA, Goble SM, Fantus RJ, et al. Outcomes in geriatric genitourinary trauma. *J Am Coll Surg* 2011 Sep;213(3):415-21.
<http://www.ncbi.nlm.nih.gov/pubmed/21723152>
4. Hurtuk M, Reed RL 2nd, Esposito TJ, et al. Trauma surgeons practice what they preach. The NTDB story on solid organ injury management. *J Trauma* 2006 Aug;61(2):243-54;discussion 254-5.
<http://www.ncbi.nlm.nih.gov/pubmed/16917435>
5. Kansas BT, Eddy MJ, Mydlo JH, et al. Incidence and management of penetrating renal trauma in patients with multiorgan injury: extended experience at an inner city trauma center. *J Urol* 2004 Oct;172(4Pt1):1355-60.
<http://www.ncbi.nlm.nih.gov/pubmed/15371841>
6. Santucci RA, Wessells H, Bartsch G, et al. Evaluation and management of renal injuries: consensus statement of the renal trauma subcommittee. *BJU Int* 2004 May;93(7):937-54.
<http://www.ncbi.nlm.nih.gov/pubmed/15142141>
7. Kuan JK, Kaufman R, Wright JL, et al. Renal injury mechanisms of motor vehicle collisions: analysis of the crash injury research and engineering network data set. *J Urol* 2007 Sep;178(3Pt1):935-40; discussion 940.
<http://www.ncbi.nlm.nih.gov/pubmed/17632156>
8. Smith TG 3rd, Wessells HB, Mack CD, et al. Examination of the impact of airbags on renal injury using a national database. *J Am Coll Surg* 2010 Sep;211(3):355-60.
<http://www.ncbi.nlm.nih.gov/pubmed/20800192>
9. Brandes SB, McAninch JW. Urban free falls and patterns of renal injury: a 20-year experience with 396 cases. *J Trauma* 1999 Oct;47(4):643-9;discussion 649-50.
<http://www.ncbi.nlm.nih.gov/pubmed/10528597>
10. Bruce LM, Croce MA, Santaniello JM, et al. Blunt renal artery injury: incidence, diagnosis, and management. *Am Surg* 2001 Jun;67(6):550-4;discussion 555-6.
<http://www.ncbi.nlm.nih.gov/pubmed/11409803>
11. Najibi S, Tannast M, Latini JM. Civilian gunshot wounds to the genitourinary tract: incidence, anatomic distribution, associated injuries, and outcomes. *Urology* 2010 Oct;76(4):977-81;discussion 981.
<http://www.ncbi.nlm.nih.gov/pubmed/20605196>
12. Moore EE, Shackford SR, Pachter HL, et al. Organ injury scaling: spleen, liver, and kidney. *J Trauma* 1989 Dec;29(12):1664-6.
<http://www.ncbi.nlm.nih.gov/pubmed/2593197>
13. Shariat SF, Roehrborn CG, Karakiewicz PI, et al. Evidence-based validation of the predictive value of the American Association for the Surgery of Trauma kidney injury scale. *J Trauma* 2007 Apr;62(4):933-9.
<http://www.ncbi.nlm.nih.gov/pubmed/17426551>
14. Kuan JK, Wright JL, Nathens AB, et al. American Association for the Surgery of Trauma Organ Injury Scale for kidney injuries predicts nephrectomy, dialysis, and death in patients with blunt injury and nephrectomy for penetrating injuries. *J Trauma* 2006 Feb;60(2):351-6.
<http://www.ncbi.nlm.nih.gov/pubmed/16508495>
15. Dugi DD 3rd, Morey AF, Gupta A, et al. American Association for the Surgery of Trauma grade 4 renal injury substratification into grades 4a (low risk) and 4b (high risk). *J Urol* 2010 Feb;183(2):592-7.
<http://www.ncbi.nlm.nih.gov/pubmed/20018329>
16. Buckley JC, McAninch JW. Revision of current American Association for the Surgery of Trauma Renal Injury grading system. *J Trauma* 2011 Jan;70(1):35-7.
<http://www.ncbi.nlm.nih.gov/pubmed/21217478>
17. Cachecho R, Millham FH, Wedel SK. Management of the trauma patient with pre-existing renal disease. *Crit Care Clin* 1994 Jul;10(3):523-36.
<http://www.ncbi.nlm.nih.gov/pubmed/792273629>
18. Sebastià MC, Rodriguez-Dobao M, Quiroga S, et al. Renal trauma in occult ureteropelvic junction obstruction: CT findings. *Eur Radiol* 1999;9(4):611-15.
<http://www.ncbi.nlm.nih.gov/pubmed/10354870>
19. Giannopoulos A, Serafetinides E, Alamanis C, et al. [Urogenital lesions diagnosed incidentally during evaluation for blunt renal injuries]. *Prog Urol* 1999 Jun;9(3):464-9. [Article in French]
<http://www.ncbi.nlm.nih.gov/pubmed/10434318>
20. Buchberger W, Penz T, Wicke K, et al. [Diagnosis and staging of blunt kidney trauma. A comparison of urinalysis, i.v. urography, sonography and computed tomography]. *Rofo* 1993 Jun;158(6):507-12. [Article in German]
<http://www.ncbi.nlm.nih.gov/pubmed/8507839>

21. Eastham JA, Wilson TG, Ahlering TE. Radiographic evaluation of adult patients with blunt renal trauma. *J Urol* 1992 Aug;148(2Pt1):266-7.
<http://www.ncbi.nlm.nih.gov/pubmed/1635113>
22. Schmidlin FR, Iselin CE, Naimi A, et al. The higher injury risk of abnormal kidneys in blunt renal trauma. *Scand J Urol Nephrol* 1998 Dec;32(6):388-92.
<http://www.ncbi.nlm.nih.gov/pubmed/9925001>
23. Chandhoke PS, McAninch JW. Detection and significance of microscopic hematuria in patients with blunt renal trauma. *J Urol* 1988 Jul;140(1):16-18.
<http://www.ncbi.nlm.nih.gov/pubmed/3379684>
24. Hoke TS, Douglas IS, Klein CL, et al. Acute renal failure after bilateral nephrectomy is associated with cytokine-mediated pulmonary injury. *J Am Soc Nephrol* 2007 Jan;18(1):155-64.
<http://www.ncbi.nlm.nih.gov/pubmed/17167117>
25. Miller KS, McAninch JW. Radiographic assessment of renal trauma: our 15-year experience. *J Urol* 1995 Aug;154(2Pt1):352-5.
<http://www.ncbi.nlm.nih.gov/pubmed/7609096>
26. Heyns CF. Renal trauma: indications for imaging and surgical exploration. *BJU Int* 2004 May;93(8):1165-70.
<http://www.ncbi.nlm.nih.gov/pubmed/15142132>
27. Mee SL, McAninch JW. Indications for radiographic assessment in suspected renal trauma. *Urol Clin North Am* 1989 May;16(2):187-92.
<http://www.ncbi.nlm.nih.gov/pubmed/2652848>
28. Rippey JC, Royse AG. Ultrasound in trauma. *Best Pract Res Clin Anaesthesiol* 2009 Sep;23(3):343-62.
<http://www.ncbi.nlm.nih.gov/pubmed/19862893>
29. Gaitini D, Razi NB, Ghersin E, et al. Sonographic evaluation of vascular injuries. *J Ultrasound Med* 2008 Jan;27(1):95-107.
<http://www.ncbi.nlm.nih.gov/pubmed/18096735>
30. Valentino M, Serra C, Zironi G, et al. Blunt abdominal trauma: emergency contrast-enhanced sonography for detection of solid organ injuries. *AJR Am J Roentgenol* 2006 May;186(5):1361-7.
<http://www.ncbi.nlm.nih.gov/pubmed/16632732>
31. Qin R, Wang P, Qin W, et al. Diagnosis and treatment of renal trauma in 298 patients. *Chin J Traumatol* 2002 Feb;5(1):21-3.
<http://www.ncbi.nlm.nih.gov/pubmed/11835751>
32. Bent C, Iyngkaran T, Power N, et al. Urological injuries following trauma. *Clin Radiol* 2008 Dec;63(12):1361-71.
<http://www.ncbi.nlm.nih.gov/pubmed/18996268>
33. Morey AF, McAninch JW, Tiller BK, et al. Single shot intraoperative excretory urography for the immediate evaluation of renal trauma. *J Urol* 1999 Apr;161(4):1088-92.
<http://www.ncbi.nlm.nih.gov/pubmed/10081844>
34. Patel VG, Walker ML. The role of 'one-shot' intravenous pyelogram in evaluation of penetrating abdominal trauma. *Am Surg* 1997 Apr;63(4):350-3.
<http://www.ncbi.nlm.nih.gov/pubmed/9124757>
35. Kawashima A, Sandler CM, Corl FM, et al. Imaging of renal trauma: a comprehensive review. *Radiographics* 2001 May-Jun;21(3):557-74.
<http://www.ncbi.nlm.nih.gov/pubmed/11353106>
36. Shima H, Nosaka S, Hayakawa M, et al. [Diagnostic imaging of renal pedicle injury]. *Nippon Igaku Hoshasen Gakkai Zasshi* 1997 Jan;57(1):5-11. [Article in Japanese]
<http://www.ncbi.nlm.nih.gov/pubmed/9038056>
37. Vasile M, Bellin MF, Hélénon O, et al. Imaging evaluation of renal trauma. *Abdom Imaging* 2000 Jul-Aug;25(4):424-30.
<http://www.ncbi.nlm.nih.gov/pubmed/10926198>
38. Uyeda JW, Anderson SW, Sakai O, et al. CT angiography in trauma. *Radiol Clin North Am* 2010 Mar;48(2):423-38.
<http://www.ncbi.nlm.nih.gov/pubmed/20609881>
39. Brown SL, Hoffman DM, Spirnak JP. Limitations of routine spiral computerized tomography in the evaluation of blunt renal trauma. *J Urol* 1998 Dec;160(6Pt1):1979-81.
<http://www.ncbi.nlm.nih.gov/pubmed/9817304>
40. Ortega SJ, Netto FS, Hamilton P, et al. CT scanning for diagnosing blunt ureteral and ureteropelvic junction injuries. *BMC Urol* 2008 Feb;8:3.
<http://www.ncbi.nlm.nih.gov/pubmed/18257927>

41. Velmahos GC, Constantinou C, Tillou A, et al. Abdominal computed tomographic scan for patients with gunshot wounds to the abdomen selected for nonoperative management. *J Trauma* 2005 Nov;59(5):1155-60;discussion 1160-1.
<http://www.ncbi.nlm.nih.gov/pubmed/16385294>
42. Eurin M, Haddad N, Zappa M, et al. Incidence and predictors of missed injuries in trauma patients in the initial hot report of whole-body CT scan. *Injury* 2012 Jan;43(1):73-7.
<http://www.ncbi.nlm.nih.gov/pubmed/21663908>
43. Ku JH, Jeon YS, Kim ME, et al. Is there a role for magnetic resonance imaging in renal trauma? *Int J Urol* 2001 Jun;8(6):261-7.
<http://www.ncbi.nlm.nih.gov/pubmed/11389740>
44. Leppänen A, Lamminen A, Tervahartiala P, et al. MRI and CT in blunt renal trauma: an update. *Semin Ultrasound CT MR* 1997 Apr;18(2):129-35.
<http://www.ncbi.nlm.nih.gov/pubmed/9163832>
45. Eastham JA, Wilson TG, Larsen DW, et al. Angiographic embolisation of renal stab wounds. *J Urol* 1992 Aug;148(2Pt1):268-70.
<http://www.ncbi.nlm.nih.gov/pubmed/1635114>
46. Shariat SF, Trinh QD, Morey AF, et al. Development of a highly accurate nomogram for prediction of the need for exploration in patients with renal trauma. *J Trauma* 2008 Jun;64(6):1451-8.
<http://www.ncbi.nlm.nih.gov/pubmed/18545108>
47. Husmann DA, Gilling PJ, Pery MO, et al. Major renal lacerations with a devitalized fragment following blunt abdominal trauma: a comparison between nonoperative (expectant) versus surgical management. *J Urol* 1993 Dec;150(6):1774-7.
<http://www.ncbi.nlm.nih.gov/pubmed/8230501>
48. Armenakas NA, Duckett CP, McAninch JW. Indications for nonoperative management of renal stab wounds. *J Urol* 1999 Mar;161(3):768-71.
<http://www.ncbi.nlm.nih.gov/pubmed/10022681>
49. Hotaling JM, Wang J, Sorensen MD, et al. A national study of trauma level designation and renal trauma outcomes. *J Urol* 2012 Feb;187(2):536-41.
<http://www.ncbi.nlm.nih.gov/pubmed/22177171>
50. Hardee MJ, Lowrance W, Brant WO, et al. High grade renal injuries: application of Parkland Hospital predictors of intervention for renal hemorrhage. *J Urol* 2013 May;189(5):1771-6.
<http://www.ncbi.nlm.nih.gov/pubmed/23219543>
51. Hagiwara A, Sakaki S, Goto H, et al. The role of interventional radiology in the management of blunt renal injury: a practical protocol. *J Trauma* 2001 Sep;51(3):526-31.
<http://www.ncbi.nlm.nih.gov/pubmed/11535904>
52. Nuss GR, Morey AF, Jenkins AC, et al. Radiographic predictors of need for angiographic embolization after traumatic renal injury. *J Trauma* 2009 Sep;67(3):578-82;discussion 582.
<http://www.ncbi.nlm.nih.gov/pubmed/19741403>
53. Huber J, Pahernik S, Hallscheidt P, et al. Selective transarterial embolisation for posttraumatic renal hemorrhage: a second try is worthwhile. *J Urol* 2011 May;185(5):1751-5.
<http://www.ncbi.nlm.nih.gov/pubmed/21420122>
54. Fu CY, Wang YC, Wu SC, et al. Angioembolisation provides benefits in patients with concomitant unstable pelvic fracture and unstable hemodynamics. *Am J Emerg Med* 2012 Jan;30(1):207-13.
<http://www.ncbi.nlm.nih.gov/pubmed/21159470>
55. Breyer BN, McAninch JW, Elliott SP, et al. Minimally invasive endovascular techniques to treat acute renal hemorrhage. *J Urol* 2008 Jun;179(6):2248-52;discussion 2253.
<http://www.ncbi.nlm.nih.gov/pubmed/18423679>
56. Sofocleous CT, Hinrichs C, Hubbi B, et al. Angiographic findings and embolotherapy in renal arterial trauma. *Cardiovasc Intervent Radiol* 2005 Jan-Feb;28(1):39-47.
<http://www.ncbi.nlm.nih.gov/pubmed/15602636>
57. Holden, A. Abdomen--interventions for solid organ injury. *Injury* 2008 Nov;39(11):1275-89
<http://www.ncbi.nlm.nih.gov/pubmed/18715559>
58. Brewer ME Jr, Strnad BT, Daley BJ, et al. Percutaneous embolisation for the management of grade 5 renal trauma in hemodynamically unstable patients: initial experience. *J Urol* 2009 Apr;181(4):1737-41.
<http://www.ncbi.nlm.nih.gov/pubmed/19233429>
59. Sarani B, Powell E, Taddeo J, et al. Contemporary comparison of surgical and interventional arteriography management of blunt renal injury. *J Vasc Interv Radiol* 2011 May;22(5):723-8.
<http://www.ncbi.nlm.nih.gov/pubmed/21514526>

60. McAninch JW, Carroll PR, Klosterman PW, et al. Renal reconstruction after injury. *J Urol* 1991 May;145(5):932-7.
<http://www.ncbi.nlm.nih.gov/pubmed/2016804>
61. Hammer CC, Santucci RA. Effect of an institutional policy of nonoperative treatment of grades I to IV renal injuries. *J Urol* 2003 May;169(5):1751-3.
<http://www.ncbi.nlm.nih.gov/pubmed/12686825>
62. Robert M, Drianno N, Muir G, et al. Management of major blunt renal lacerations: surgical or nonoperative approach? *Eur Urol* 1996;30(3):335-9.
<http://www.ncbi.nlm.nih.gov/pubmed/8931966>
63. Gonzalez RP, Falimirski M, Holevar MR, et al. Surgical management of renal trauma: is vascular control necessary? *J Trauma* 1999 Dec;47(6):1039-42;discussion 1042-4.
<http://www.ncbi.nlm.nih.gov/pubmed/10608530>
64. Atala A, Miller FB, Richardson JD, et al. Preliminary vascular control for renal trauma. *Surg Gynecol Obstet* 1991 May;172(5):386-90.
<http://www.ncbi.nlm.nih.gov/pubmed/2028374>
65. Chaabouni MN, Bittard M. [Application of a peri-renal prosthesis (vicryl mesh) in the conservative treatment of multiple ruptured kidney fragments]. *Ann Urol (Paris)* 1996;30(2):61-3. [Article in French]
<http://www.ncbi.nlm.nih.gov/pubmed/8767808>
66. Master VA, McAninch JW. Operative management of renal injuries: parenchymal and vascular. *Urol Clin North Am* 2006 Feb;33(1):21-31.
<http://www.ncbi.nlm.nih.gov/pubmed/16488277>
67. Davis KA, Reed RL 2nd, Santaniello J, et al. Predictors of the need for nephrectomy after renal trauma. *J Trauma* 2006 Jan;60(1):164-9;discussion 169-70.
<http://www.ncbi.nlm.nih.gov/pubmed/16456451>
68. Wright JL, Nathens AB, Rivara FP, et al. Renal and extrarenal predictors of nephrectomy from the national trauma data bank. *J Urol* 2006 Mar;175(3Pt1):970-5;discussion 975.
<http://www.ncbi.nlm.nih.gov/pubmed/16469594>
69. DiGiacomo JC, Rotondo MF, Kauder DR, et al. The role of nephrectomy in the acutely injured. *Arch Surg* 2001 Sep;136(9):1045-9.
<http://www.ncbi.nlm.nih.gov/pubmed/11529828>
70. Brandes SB, McAninch JW. Reconstructive surgery for trauma of the upper urinary tract. *Urol Clin North Am* 1999 Feb;26(1):183-99.
<http://www.ncbi.nlm.nih.gov/pubmed/10086060>
71. McAninch JW, Dixon CM, Carroll PR. [The surgical treatment of renal trauma]. *Vestn Khir Im I I Grek* 1990 Nov;145(11):64-72. [Article in Russian]
<http://www.ncbi.nlm.nih.gov/pubmed/1966179>
72. Shekarriz B, Stoller ML. The use of fibrin sealant in urology. *J Urol* 2002 Mar;167(3):1218-25.
<http://www.ncbi.nlm.nih.gov/pubmed/11832701>
73. Knudson MM, Harrison PB, Hoyt DB, et al. Outcome after major renovascular injuries: a Western trauma association multicenter report. *J Trauma* 2000 Dec;49(6):1116-22.
<http://www.ncbi.nlm.nih.gov/pubmed/11130498>
74. Tillou A, Romero J, Asensio JA, et al. Renal vascular injuries. *Surg Clin North Am* 2001 Dec;81(6):417-30.
<http://www.ncbi.nlm.nih.gov/pubmed/11766183>
75. Santucci RA, Fisher MB. The literature increasingly supports expectant (conservative) management of renal trauma--a systematic review. *J Trauma* 2005 Aug;59(2):493-503.
<http://www.ncbi.nlm.nih.gov/pubmed/16294101>
76. Schmidlin FR, Rohner S, Hadaya K, et al. [The conservative treatment of major kidney injuries]. *Ann Urol (Paris)* 1997;31(5):246-52. [Article in French]
<http://www.ncbi.nlm.nih.gov/pubmed/9480627>
77. Holmes JF, McGahan JP, Wisner DH. Rate of intra-abdominal injury after a normal abdominal computed tomographic scan in adults with blunt trauma. *Am J Emerg Med* 2012 May;30(4):574-9.
<http://www.ncbi.nlm.nih.gov/pubmed/21641163>
78. Alsikafi NF, McAninch JW, Elliott SP, et al. Nonoperative management outcomes of isolated urinary extravasation following renal lacerations due to external trauma. *J Urol* 2006 Dec;176(6Pt1):2494-7.
<http://www.ncbi.nlm.nih.gov/pubmed/17085140>
79. Santucci RA, McAninch JM. Grade IV renal injuries: evaluation, treatment, and outcome. *World J Surg* 2001 Dec;25(12):1565-72.
<http://www.ncbi.nlm.nih.gov/pubmed/11775193>

80. Altman AL, Haas C, Dinchman KH, et al. Selective nonoperative management of blunt grade 5 Renal injury. *J Urol* 2000 Jul;164(1):27-30;discussion 30-1.
<http://www.ncbi.nlm.nih.gov/pubmed/10840417>
81. Moudouni SM, Hadj Slimen M, Manunta A, et al. Management of major blunt renal lacerations: is a nonoperative approach indicated? *Eur Urol* 2001 Oct;40(4):409-14.
<http://www.ncbi.nlm.nih.gov/pubmed/11713395>
82. Husmann DA, Morris JS. Attempted nonoperative management of blunt renal lacerations Extending through the corticomedullary junction: the short-term and long-term sequelae. *J Urol* 1990 Apr;143(4):682-4.
<http://www.ncbi.nlm.nih.gov/pubmed/2313792>
83. Elliott SP, Olweny EO, McAninch JW. Renal arterial injuries: a single center analysis of management strategies and outcomes. *J Urol* 2007 Dec;178(6):2451-5.
<http://www.ncbi.nlm.nih.gov/pubmed/17937955>
84. Jawas A, Abu-Zidan FM. Management algorithm for complete blunt renal artery occlusion in multiple trauma patients: case series. *Int J Surg* 2008 Aug;6(4):317-22.
<http://www.ncbi.nlm.nih.gov/pubmed/18590988>
85. Jansen JO, Inaba K, Resnick S, et al. Selective non-operative management of abdominal gunshot wounds: survey of practise. *Injury* 2013 May;44(5):639-44.
<http://www.ncbi.nlm.nih.gov/pubmed/22341771>
86. Buckley JC, McAninch JW. Selective management of isolated and nonisolated grade IV renal injuries. *J Urol* 2006 Dec;176(6Pt1):2498-502;discussion 2502.
<http://www.ncbi.nlm.nih.gov/pubmed/17085141>
87. Velmahos GC, Demetriades D, Cornwell EE 3rd, et al. Selective management of renal gunshot wounds. *Br J Surg* 1998 Aug;85(8):1121-4.
<http://www.ncbi.nlm.nih.gov/pubmed/9718011>
88. Baniel J, Schein M. The management of penetrating trauma to the urinary tract. *J Am Coll Surg* 1994 Apr;178(4):417-25.
<http://www.ncbi.nlm.nih.gov/pubmed/8149045>
89. DuBose J, Inaba K, Teixeira PG, et al. Selective non-operative management of solid organ injury following abdominal gunshot wounds. *Injury* 2007 Sep;38(9):1084-90.
<http://www.ncbi.nlm.nih.gov/pubmed/17544428>
90. Shefler A, Gremitzky A, Vainrib M, et al. [The role of nonoperative management of penetrating renal trauma]. *Harefuah* 2007 May;146(5):345-8, 406-7. [Article in Hebrew]
<http://www.ncbi.nlm.nih.gov/pubmed/17674549>
91. Hope WW, Smith ST, Medieros B, et al. Non-operative management in penetrating abdominal trauma: is it feasible at a Level II trauma center? *J Emerg Med* 2012 Jul;43(1):190-5.
<http://www.ncbi.nlm.nih.gov/pubmed/22051843>
92. Bernath AS, Schutte H, Fernandez RR, et al. Stab wounds of the kidney: conservative management in flank penetration. *J Urol* 1983 Mar;129(3):468-70.
<http://www.ncbi.nlm.nih.gov/pubmed/6834529>
93. Wessells H, McAninch JW, Meyer A, et al. Criteria for nonoperative treatment of significant penetrating renal lacerations. *J Urol* 1997 Jan;157(1):24-7.
<http://www.ncbi.nlm.nih.gov/pubmed/8976207>
94. Blankenship JC, Gavant ML, Cox CE, et al. Importance of delayed imaging for blunt renal trauma. *World J Surg* 2001 Dec;25(12):1561-4.
<http://www.ncbi.nlm.nih.gov/pubmed/11775192>
95. McGuire J, Bultitude MF, Davis P, et al. Predictors of outcome for blunt high grade renal injury treated with conservative intent. *J Urol* 2011 Jan;185(1):187-91.
<http://www.ncbi.nlm.nih.gov/pubmed/21074795>
96. Wessells H, Deirmenjian J, McAninch JW. Preservation of renal function after reconstruction for trauma: quantitative assessment with radionuclide scintigraphy. *J Urol* 1997 May;157(5):1583-6.
<http://www.ncbi.nlm.nih.gov/pubmed/9112481>
97. Fiard G, Rambeaud JJ, Descotes JL, et al. Long-term renal function assessment with dimercaptosuccinic acid scintigraphy after conservative treatment of major renal trauma. *J Urol* 2012 Apr;187(4):1306-9.
<http://www.ncbi.nlm.nih.gov/pubmed/22341289>
98. Dunfee BL, Lucey BC, Soto JA. Development of renal scars on CT after abdominal trauma: does grade of injury matter? *AJR Am J Roentgenol* 2008 May;190(5):1174-9.
<http://www.ncbi.nlm.nih.gov/pubmed/18430828>

99. Heyns CF, van Vollenhoven P. Increasing role of angiography and segmental artery embolisation in the management of renal stab wounds. *J Urol* 1992 May;147(5):1231-4.
<http://www.ncbi.nlm.nih.gov/pubmed/1569655>
100. Monstrey SJ, Beerthuizen GI, vander Werken C, et al. Renal trauma and hypertension. *J Trauma* 1989 Jan;29(1):65-70.
<http://www.ncbi.nlm.nih.gov/pubmed/2911106>
101. Lebech A, Strange-Vognsen HH. [Hypertension following blunt kidney injury]. *Ugeskr Laeger* 1990 Apr;152(14):994-7. [Article in Danish]
<http://www.ncbi.nlm.nih.gov/pubmed/2183457>
102. Montgomery RC, Richardson JD, Harty JI. Posttraumatic renovascular hypertension after occult renal injury. *J Trauma* 1998 Jul;45(1):106-10.
<http://www.ncbi.nlm.nih.gov/pubmed/9680021>
103. Haas CA, Reigle MD, Selzman AA, et al. Use of ureteral stents in the management of major renal trauma with urinary extravasation: is there a role? *J Endourol* 1998 Dec;12(6):545-9.
<http://www.ncbi.nlm.nih.gov/pubmed/9895260>
104. Matthews LA, Smith EM, Spirnak JP. Nonoperative treatment of major blunt renal lacerations with urinary extravasation. *J Urol* 1997 Jun;157(6):2056-8.
<http://www.ncbi.nlm.nih.gov/pubmed/9146579>
105. Wang KT, Hou CJ, Hsieh JJ, et al. Late development of renal arteriovenous fistula following gunshot trauma - a case report. *Angiology* 1998 May;49(5):415-18.
<http://www.ncbi.nlm.nih.gov/pubmed/9591535>
106. Salazar GM, Walker TG. Evaluation and management of acute vascular trauma. *Tech Vasc Interv Radiol* 2009 Jun;12(2):102-16.
<http://www.ncbi.nlm.nih.gov/pubmed/19853228>
107. Miller DC, Forauer A, Faerber GJ. Successful angioembolisation of renal artery pseudoaneurysms after blunt abdominal trauma. *Urology* 2002 Mar;59(3):444.
<http://www.ncbi.nlm.nih.gov/pubmed/11880095>
108. Harrington TG, Kandel LB. Renal colic following a gunshot wound to the abdomen: the birdshot calculus. *J Urol* 1997 Apr;157(4):1351-2.
<http://www.ncbi.nlm.nih.gov/pubmed/9120940>
109. Park JK, Yang SO, Park SC. Duodenal obstruction by retroperitoneal hematoma induced by severe blunt renal trauma. *J Urol* 2001 Jun;165(6Pt1):1993-4.
<http://www.ncbi.nlm.nih.gov/pubmed/11371904>
110. Rosen MA, McAninch JW. Management of combined renal and pancreatic trauma. *J Urol* 1994 Jul;152(1):22-5.
<http://www.ncbi.nlm.nih.gov/pubmed/8201670>
111. Wessells H, McAninch JW. Effect of colon injury on the management of simultaneous renal trauma. *J Urol* 1996 Jun;155(6):1852-6.
<http://www.ncbi.nlm.nih.gov/pubmed/8618272>
112. Sartorelli KH, Frumiento C, Rogers FB, et al. Nonoperative management of hepatic, splenic, and renal injuries in adults with multiple injuries. *J Trauma* 2000 Jul;49(1):56-61.
<http://www.ncbi.nlm.nih.gov/pubmed/10912858>
113. Heye S, Vanbeckevoort D, Blockmans D, et al. Iatrogenic main renal artery injury: treatment by endovascular stent-graft placement. *Cardiovasc Intervent Radiol* 2005 Jan-Feb;28(1):93-4.
<http://www.ncbi.nlm.nih.gov/pubmed/15602634>
114. Maleux G, Messiaen T, Stockx L, et al. Transcatheter embolisation of biopsy-related vascular injuries in renal allografts. Long-term technical, clinical and biochemical results. *Acta Radiol* 2003 Jan;44(1):13-7.
<http://www.ncbi.nlm.nih.gov/pubmed/12630992>
115. Albani JM, Novick AC. Renal artery pseudoaneurysm after partial nephrectomy: three case reports and a literature review. *Urology* 2003 Aug;62(2):227-31.
<http://www.ncbi.nlm.nih.gov/pubmed/12893324>
116. Furness PN, Philpott CM, Chorbadian MT, et al. Protocol biopsy of the stable renal transplant: a multicenter study of methods and complication rates. *Transplantation* 2003 Sep;76(6):969-73.
<http://www.ncbi.nlm.nih.gov/pubmed/14508363>
117. Barley FL, Kessel D, Nicholson T, et al. Selective embolization of large symptomatic iatrogenic renal transplant arteriovenous fistula. *Cardiovasc Intervent Radiol* 2006 Nov-Dec;29(6):1084-7.
<http://www.ncbi.nlm.nih.gov/pubmed/16794894>
118. Takahashi M, Humke U, Girndt M, et al. Early posttransplantation renal allograft perfusion failure due to dissection: diagnosis and interventional treatment. *AJR Am J Roentgenol* 2003 Mar;180(3):759-63.
<http://www.ncbi.nlm.nih.gov/pubmed/12591692>

119. Bellman GC. Complications of endopyelotomy. *J Endourol* 1996 Apr;10(2):177-81.
<http://www.ncbi.nlm.nih.gov/pubmed/8728685>
120. Hinshaw JL, Shadid AM, Nakada SY, et al. Comparison of percutaneous and laparoscopic cryoablation for the treatment of solid renal masses. *AJR Am J Roentgenol* 2008 Oct;191(4):1159-68.
<http://www.ncbi.nlm.nih.gov/pubmed/18806159>
121. Jones CD, McGahan JP. Computed tomographic evaluation and guided correction of malpositioned nephrostomy catheters. *Abdom Imaging* 1999 Jul-Aug;24(4):422-5.
<http://www.ncbi.nlm.nih.gov/pubmed/10390572>
122. Lewis S, Patel U. Major complications after percutaneous nephrostomy - lessons from a department audit. *Clin Radiol* 2004 Feb;59(2):171-9.
<http://www.ncbi.nlm.nih.gov/pubmed/14746788>
123. Phadke RV, Sawlani V, Rastogi H, et al. Iatrogenic renal vascular injuries and their radiological management. *Clin Radiol* 1997 Feb;52(2):119-23.
<http://www.ncbi.nlm.nih.gov/pubmed/9043045>
124. Cohenpour M, Strauss S, Gottlieb P, et al. Pseudoaneurysm of the renal artery following partial nephrectomy: imaging findings and coil embolisation. *Clin Radiol* 2007 Nov;62(11):1104-9.
<http://www.ncbi.nlm.nih.gov/pubmed/17920871>
125. Loffroy R, Guiu B, Lambert A, et al. Management of post-biopsy renal allograft arteriovenous fistulas with selective arterial embolisation: immediate and long-term outcomes. *Clin Radiol* 2008 Jun;63(6):657-65.
<http://www.ncbi.nlm.nih.gov/pubmed/18455557>
126. Ben Meir D, Lask D, Koren R, et al. Intrarenal foreign body presenting as a solid tumor. *Urology* 2003 May;61(5):1035.
<http://www.ncbi.nlm.nih.gov/pubmed/12736036>
127. Nakada SY, Johnson M. Ureteropelvic junction obstruction. Retrograde endopyelotomy. *Urol Clin North Am* 2000 Nov;27(4):677-84.
<http://www.ncbi.nlm.nih.gov/pubmed/11098766>
128. Silberzweig JE, Tey S, Winston JA, et al. Percutaneous renal biopsy complicated by renal capsular artery pseudoaneurysm. *Am J Kidney Dis* 1998 Mar;31(3):533-5.
<http://www.ncbi.nlm.nih.gov/pubmed/9506693>
129. Gupta M, Bellman GC, Smith AD. Massive hemorrhage from renal vein injury during percutaneous renal surgery: endourological management. *J Urol* 1997 Mar;157(3):795-7.
<http://www.ncbi.nlm.nih.gov/pubmed/9072568>
130. El-Nahas AR, Shokeir AA, El-Assmy AM, et al. Post-percutaneous nephrolithotomy extensive hemorrhage: a study of risk factors. *J Urol* 2007 Feb;177(2):576-9.
<http://www.ncbi.nlm.nih.gov/pubmed/17222636>
131. El-Nahas AR, Shokeir AA, Mohsen T, et al. Functional and morphological effects of postpercutaneous nephrolithotomy superselective renal angiographic embolisation. *Urology* 2008 Mar;71(3):408-12.
<http://www.ncbi.nlm.nih.gov/pubmed/18342174>
132. Ghai B, Dureja GP, Arvind P. Massive intraabdominal extravasation of fluid: a life threatening complication following percutaneous nephrolithotomy. *Int Urol Nephrol* 2003;35(3):315-18.
<http://www.ncbi.nlm.nih.gov/pubmed/15160530>
133. Oderich GS, Panneton JM, Hofer J, et al. Iatrogenic operative injuries of abdominal and pelvic veins: a potentially lethal complication. *J Vasc Surg* 2004 May;39(5):931-6.
<http://www.ncbi.nlm.nih.gov/pubmed/15111840>
134. Taneja M, Tan KT. Renal vascular injuries following nephron-sparing surgery and their endovascular management. *Singapore Med J* 2008 Jan;49(1):63-6.
<http://www.ncbi.nlm.nih.gov/pubmed/18204772>
135. Inci K, Cil B, Yazici S, Peynircioglu B, et al. Renal artery pseudoaneurysm: complication of minimally invasive kidney surgery. *J Endourol* 2010 Jan;24(1):149-54.
<http://www.ncbi.nlm.nih.gov/pubmed/19954351155>
136. Perini S, Gordon RL, LaBerge JM, et al. Transcatheter embolisation of biopsy-related vascular injury in the transplant kidney: immediate and long-term outcome. *J Vasc Interv Radiol* 1998 Nov-Dec;9(6):1011-9.
<http://www.ncbi.nlm.nih.gov/pubmed/9840051>
137. Nakatani T, Uchida J, Han YS, et al. Renal allograft arteriovenous fistula and large pseudoaneurysm. *Clin Transplant* 2003 Feb;17(1):9-12.
<http://www.ncbi.nlm.nih.gov/pubmed/12588315>

138. Dorffner R, Thurnher S, Prokesch R, et al. Embolisation of iatrogenic vascular injuries of renal transplants: immediate and follow-up results. *Cardiovasc Intervent Radiol* 1998 Mar-Apr;21(2):129-34. <http://www.ncbi.nlm.nih.gov/pubmed/9502679>
139. Wang MQ, Xie CM, Wang ZP, et al. [Treatment of acquired arteriovenous fistulas with interventional minimally invasive techniques]. [Article in Chinese] *Zhonghua Wai Ke Za Zhi* 2004 Jun;42(11): 687-91. <http://www.ncbi.nlm.nih.gov/pubmed/15329261>
140. Morris CS, Bonnevie GJ, Najarian KE. Nonsurgical treatment of acute iatrogenic renal artery injuries occurring after renal artery angioplasty and stenting. *AJR Am J Roentgenol* 2001 Dec;177(6):1353-7. <http://www.ncbi.nlm.nih.gov/pubmed/11717082>

3. URETERAL TRAUMA

Trauma to the ureters is relatively rare because they are protected from injury by their small size, mobility, and the adjacent vertebrae, bony pelvis, and muscles. Iatrogenic ureteral trauma gives rise to the commonest cause of ureteral injury. It is seen in open, laparoscopic or endoscopic surgery and is often missed intraoperatively. Any trauma to the ureter may result in severe sequelae.

3.1 Aetiology

Overall, ureteral trauma accounts for 1-2.5% of urinary tract trauma (1-4), but this rate is even higher in modern combat injuries (5). Penetrating external ureteral trauma, mainly caused by gunshot wounds, dominates most of the modern series, both civilian and military (1,3,6). About one-third of cases of external trauma to the ureters are caused by blunt trauma, mostly road traffic injuries (2,4).

Ureteral injury should be suspected in all cases of penetrating abdominal injury, especially gunshot wounds, because it occurs in 2-3% of cases (1). It should also be suspected in blunt trauma involving deceleration as the renal pelvis can be torn away from the ureter (1). In external ureteral trauma, the relative frequency of injury site in the ureter varies between series, but it is more common in the upper ureter (2-4). Iatrogenic ureteral trauma can result from various mechanisms: ligation or kinking with a suture, crushing from a clamp, partial or complete transection, thermal injury, or ischaemia from devascularisation (6-8). Gynaecological operations are the commonest cause of iatrogenic trauma to the ureters (Table 3.1) and usually involve damage to the lower ureter (1,6,7,9). Ureteral damage may also be caused by colorectal operations, especially abdominoperineal resection and sigmoid colectomy. The incidence of ureteral injury during laparoscopic colectomy is higher than in open surgery (10). Iatrogenic injury during ureteroscopy is usually minor, though occasionally it can be serious, e.g. complete ureteral avulsion. Long-term strictures are relatively rare - less than 1% in most series (11).

The incidence of urological iatrogenic trauma has decreased in the last 20 years (6,11) due to improvements in technique, instruments and surgical experience. Risk factors for iatrogenic trauma include conditions that alter the normal anatomy, e.g. advanced malignancy, prior surgery or irradiation, diverticulitis, endometriosis, anatomical abnormalities, and major haemorrhage (6,10,12). Nevertheless, most cases have no identifiable risk factors (6,8,13). Occult ureteral injury occurs more often than reported and not all injuries are diagnosed intraoperatively. In gynaecological surgery, if routine intraoperative cystoscopy is used, the detection rate of ureteral trauma is five times higher than usually reported (12,14).

Table 3.1: Incidence of ureteral injury in various procedures

| Procedure | Percentage % |
|--|--------------|
| Gynaecological (9,15,16) | |
| Vaginal hysterectomy | 0.02 - 0.5 |
| Abdominal hysterectomy | 0.03 - 2.0 |
| Laparoscopic hysterectomy | 0.2 - 6.0 |
| Urogynaecological (anti-incontinence/prolapse) | 1.7 - 3.0 |
| Colorectal (8,10,17) | 0.15 - 10 |
| Ureteroscopy (11) | |
| Mucosal abrasion | 0.3 - 4.1 |
| Ureteral perforation | 0.2 - 2.0 |
| Intussusception / avulsion | 0 - 0.3 |

3.2 Diagnosis

The diagnosis of ureteral trauma can be challenging. In penetrating external trauma, it is usually made intraoperatively during laparotomy (18), but it is delayed in most blunt trauma and iatrogenic cases (6,9,19). A high index of suspicion should be maintained.

3.2.1 Clinical diagnosis

External ureteral trauma usually accompanies severe abdominal and pelvic injuries. Penetrating trauma is usually associated with vascular and intestinal injuries, while blunt trauma is associated with damage to the pelvic bones and lumbosacral spine (2,4). Haematuria is unreliable and a poor indicator of ureteral injury, as it is present in only 50-75% of patients (1,6,20).

Iatrogenic injury may be noticed during the primary procedure, when intravenous dye (e.g. indigo carmine) can be injected to exclude ureteral injury. It may also be noticed later, when it is typically discovered by subsequent evidence of upper tract obstruction, urinary fistulae formation or sepsis. The following clinical signs are characteristic of delayed diagnosis: flank pain, urinary incontinence, vaginal or drain urinary leakage, haematuria, fever, uraemia or urinoma.

When the diagnosis is missed, the complication rate increases (1,5,19). Early recognition facilitates immediate repair and provides better outcome. Prolonged ureteral obstruction (> 2 weeks) predisposes the patient to pain and risk of infection (16) generally results in irreversible renal damage, and almost doubles the risk of hypertension (21).

3.2.2 Radiological diagnosis

Extravasation of contrast medium in computerised tomography (CT) or in IVP is the hallmark sign of ureteral trauma. However, it is often only hydronephrosis, ascites, urinoma or mild ureteral dilation that are noticed. In unclear cases, a retrograde or antegrade urography is the gold standard for confirmation (6). Intravenous pyelography, especially one-shot IVP, is unreliable in diagnosis, as it is negative in up to 60% of patients (1,6). With the increasing use of CT scanning in polytrauma patients, the diagnosis of external ureteral trauma is increasingly made radiographically before the clinical signs.

3.3 Prevention of iatrogenic trauma

The prevention of iatrogenic trauma to the ureters depends upon the visual identification of the ureters and careful intraoperative dissection in their proximity (6-8). The use of prophylactic preoperative ureteral stent insertion assists in visualisation and palpation and is often used in complicated cases. It is probably also useful in secondary prevention by making it easier to detect ureteral injury (7), however, it does not decrease the rate of injury (6). Apart from its evident disadvantages (potential complications and cost), a stent may alter the location of the ureter and diminish its flexibility (7,17). Routine prophylactic stenting is generally not cost-effective (7). In hysterectomy, it was estimated to become cost-effective when the rate of injury exceeded 3.2% (12), and it is therefore advocated only in selected patients with risk factors (17).

Another form of secondary prevention is intraoperative cystoscopy after intravenous dye injection, which can provide confirmation of ureteral patency (9). Routine cystoscopy has minimal risks and markedly increases the rate of ureteral injury detection (14). However, there are significant costs to its universal use. It has been estimated to be cost-saving for benign gynaecological operations with a threshold of injury above the rate of 1.5-2% (9).

3.4 Management

Management of ureteral trauma depends on many factors concerning the nature, severity and location of the injury. Immediate diagnosis of a ligation injury during an operation can be managed by de-ligation and stent placement. Partial injuries can be repaired immediately with a stent or urine diversion by a nephrostomy tube. Stenting is helpful because it provides canalisation and may decrease the risk of stricture (6). On the other hand, its insertion has to be weighed against potentially aggravating the ureteral injury. Immediate repair of ureteral injury is usually advisable. However, in unstable trauma patients, a 'damage control' approach is preferred with ligation of the ureter, diversion of the urine (e.g. by a nephrostomy), and a delayed definitive repair (22). Injuries that are diagnosed late are usually treated first by a nephrostomy tube with or without a stent (6). Retrograde stenting is often unsuccessful in this setting.

The endourological treatment of small ureteral fistulae and strictures is safe and effective in selected cases (23), but an open surgical repair is often necessary. Laparoscopic and robotic repairs of ureteral injuries are increasingly common in the literature (24). The basic principles for any surgical repair of a ureteral injury are outlined in Table 3.2, while the various options for surgical reconstruction are given in Table 3.3. Proximal and mid-ureteral injuries can often be managed by primary uretero-ureterostomy, while a distal injury is often treated with ureteral reimplantation. Wide debridement is highly recommended for gunshot wound injuries due to the 'blast effect' of the injury.

Table 3.2: Principles of surgical repair of ureteral injury

| Principles of surgical repair of ureteral injury |
|---|
| Debridement of necrotic tissue |
| Spatulation of ureteral ends |
| Watertight mucosa-to-mucosa anastomosis with absorbable sutures |
| Internal stenting |
| External drain |
| Isolation of injury with peritoneum or omentum |

Table 3.3: Reconstruction option by site of injury

| Site of injury | Reconstruction options |
|-----------------------|---|
| Upper ureter | Uretero-ureterostomy Transuretero-ureterostomy Uretero-calycostomy |
| Mid ureter | Uretero-ureterostomy Transuretero-ureterostomy Ureteral reimplantation and a Boari flap |
| Lower ureter | Ureteral reimplantation Ureteral reimplantation with a psoas hitch |
| Complete | Ileal interposition graft Autotransplantation |

3.4.1 Uretero-ureterostomy

A uretero-ureterostomy is the most common repair performed (1), usually in the upper and mid-ureter.

3.4.2 Uretero-calycostomy

In pelvic-ureteral junction or upper ureteral injury, the ureter can be anastomosed to a lower pole calyx of the ipsilateral kidney.

3.4.3 Transuretero-ureterostomy

The distal end of the injured ureter is ligated. The proximal end is transposed across the midline through a retroperitoneal window and anastomosed to the contralateral ureter. This is a valid option in extensive ureteral loss or when pelvic injuries preclude ureteral reimplantation.

3.4.4 Ureteral reimplantation with a psoas hitch

Distal ureteral injuries are best managed by ureteral reimplantation because the primary trauma usually jeopardises the blood supply to the distal ureter. The question of refluxing vs. non-refluxing ureteral reimplantation remains unresolved in the literature. The risk for clinically significant reflux should be weighed against the risk for ureteral obstruction.

A psoas hitch with non-absorbable sutures between the bladder and the ipsilateral psoas tendon is usually needed to bridge the gap and to protect the anastomosis from tension. It is important to avoid the genitofemoral nerve. The contralateral superior vesical pedicle may be divided to improve bladder mobility.

3.4.5 Ureteral reimplantation with a Boari flap

In extensive mid-lower ureteral injury, the large gap can be bridged with a tubularised L-shaped bladder flap. It is a time-consuming operation and not usually suitable in the acute setting.

3.4.6 Ileal interposition graft

If it is necessary to replace the entire ureter or a long ureteral segment, the ureter can be replaced using a segment of the intestines, usually the ileum. This should be avoided in patients with impaired renal function or known intestinal disease. The ileal segment is placed in the isoperistaltic orientation between the renal pelvis and the bladder. Follow-up should include serum chemistry to diagnose hyperchloremic metabolic acidosis (25). A review of long-term complications reported complication rates of 3% anastomotic stricture and 6% fistulae (26).

3.4.7 Autotransplantation

In cases of extensive ureteral loss or after multiple attempts at ureteral repair, the kidney can be relocated to the pelvis. The renal vessels are anastomosed to the iliac vessels and a ureteral reimplantation is performed (27).

3.5 Statements and recommendations on ureteral trauma

| Statements | LE |
|---|----|
| Iatrogenic ureteral trauma gives rise to the commonest cause of ureteral injury. | 3 |
| Gunshot wounds account for the majority of penetrating ureteral trauma, while motor vehicle accidents account for most of blunt injuries. | 3 |
| Ureteral trauma usually accompanies severe abdominal and pelvic injuries. | 3 |
| Haematuria is unreliable and a poor indicator of ureteral injury. | 3 |
| The diagnosis of ureteral trauma is often delayed. | 2 |
| Preoperative prophylactic stents do not prevent ureteral injury, but may assist in its detection. | 2 |
| Endourological treatment of small ureteral fistulae and strictures is safe and effective. | 3 |
| Major ureteral injury requires ureteral reconstruction following temporary urinary diversion. | 3 |

| Recommendations | GR |
|---|----|
| Visual identification of the ureters and meticulous dissection in their vicinity are mandatory to prevent ureteral trauma during abdominal and pelvic surgery. | A* |
| High level of suspicion for ureteral injury should be maintained in all abdominal penetrating trauma, and in deceleration-type blunt trauma. | A* |
| Preoperative prophylactic stents do not prevent ureteral injury and therefore it is recommended that it be used in selected cases (based on risk factors and surgeon's experience). | B |

*Upgraded following panel consensus.

3.6 References

- Elliott SP, McAninch JW. Ureteral injuries: external and iatrogenic. *Urol Clin North Am* 2006 Feb;33(1):55-66.
<http://www.ncbi.nlm.nih.gov/pubmed/16488280>
- McGeady JB, Breyer BN. Current epidemiology of genitourinary trauma. *Urol Clin North Am* 2013 Aug;40(3):323-34.
<http://www.ncbi.nlm.nih.gov/pubmed/23905930>
- Pereira BM, Ogilvie MP, Gomez-Rodriguez JC, et al. A review of ureteral injuries after external trauma. *Scand J Trauma Resusc Emerg Med* 2010 Feb;18:6.
<http://www.ncbi.nlm.nih.gov/pubmed/20128905>
- Siram SM, Gerald SZ, Greene WR, et al. Ureteral trauma: patterns and mechanisms of injury of an uncommon condition. *Am J Surg* 2010 Apr;199(4):566-70.
<http://www.ncbi.nlm.nih.gov/pubmed/20359576>
- Serkin FB, Soderdahl DW, Hernandez J, et al. Combat urologic trauma in US military overseas contingency operations. *J Trauma* 2010 Jul;69 Suppl 1:S175-8.
<http://www.ncbi.nlm.nih.gov/pubmed/20622614>
- Brandes S, Coburn M, Armenakas N, et al. Diagnosis and management of ureteric injury: an evidence based analysis. *BJU Int* 2004 Aug;94(3):277-89.
<http://www.ncbi.nlm.nih.gov/pubmed/15291852>
- Chou MT, Wang CJ, Lien RC. Prophylactic ureteral catheterization in gynecologic surgery: a 12-year randomized trial in a community hospital. *Int Urogynecol J Pelvic Floor Dysfunct* 2009 Jun;20(6): 689-93.
<http://www.ncbi.nlm.nih.gov/pubmed/19165412>
- Delacroix SE Jr, Winters JC. Urinary tract injuries: recognition and management. *Clin Colon Rectal Surg* 2010 Jun;23(2):104-12.
<http://www.ncbi.nlm.nih.gov/pubmed/21629628>
- Visco AG, Taber KH, Weidner AC, et al. Cost-effectiveness of universal cystoscopy to identify ureteral injury at hysterectomy. *Obstet Gynecol* 2001 May;97(5 Pt 1):685-92.
<http://www.ncbi.nlm.nih.gov/pubmed/11339916>
- Palaniappa NC, Telem DA, Ranasinghe NE, Divino CM. Incidence of iatrogenic ureteral injury after laparoscopic colectomy. *Arch Surg* 2012 Mar;147(3):267-71.
<http://www.ncbi.nlm.nih.gov/pubmed/22430909>

11. Johnson DB, Pearle MS. Complications of ureteroscopy. *Urol Clin North Am* 2004 Feb;31(1):157-71.
<http://www.ncbi.nlm.nih.gov/pubmed/15040412>
12. Schimpf MO, Gottenger EE, Wagner JR. Universal ureteral stent placement at hysterectomy to identify ureteral injury: a decision analysis. *BJOG* 2008 Aug;115(9):1151-8.
<http://www.ncbi.nlm.nih.gov/pubmed/18518875>
13. Vakili B, Chesson RR, Kyle BL, et al. The incidence of urinary tract injury during hysterectomy: a prospective analysis based on universal cystoscopy. *Am J Obstet Gynecol* 2005 May;192(5):1599-604.
<http://www.ncbi.nlm.nih.gov/pubmed/15902164>
14. Gilmour DT, Das S, Flowerdew G. Rates of urinary tract injury from gynecologic surgery and the role of intraoperative cystoscopy. *Obstet Gynecol* 2006 Jun;107(6):1366-72.
<http://www.ncbi.nlm.nih.gov/pubmed/16738165>
15. De Cicco C, Ret Davalos ML, Van Cleynenbreugel B, et al. Iatrogenic ureteral lesions and repair: a review for gynecologists. *J Minim Invasive Gynecol* 2007 Jul-Aug;14(4):428-35.
<http://www.ncbi.nlm.nih.gov/pubmed/17630159>
16. Wu HH, Yang PY, Yeh GP, et al. The detection of ureteral injuries after hysterectomy. *J Minim Invasive Gynecol* 2006 Sep-Oct;13(5):403-8.
<http://www.ncbi.nlm.nih.gov/pubmed/16962522>
17. Pokala N, Delaney CP, Kiran RP, et al. A randomized controlled trial comparing simultaneous intraoperative vs sequential prophylactic ureteric catheter insertion in re-operative and complicated colorectal surgery. *Int J Colorectal Dis* 2007 Jun;22(6):683-7.
<http://www.ncbi.nlm.nih.gov/pubmed/17031654>
18. Kunkle DA, Kansas BT, Pathak A, et al. Delayed diagnosis of traumatic ureteral injuries. *J Urol* 2006 Dec;176(6 Pt 1):2503-7.
<http://www.ncbi.nlm.nih.gov/pubmed/17085143>
19. Parpala-Sparman T, Paananen I, Santala M, et al. Increasing numbers of ureteric injuries after the introduction of laparoscopic surgery. *Scand J Urol Nephrol* 2008;42(5):422-7.
<http://www.ncbi.nlm.nih.gov/pubmed/18609278>
20. Medina D, Lavery R, Ross SE, et al. Ureteral trauma: preoperative studies neither predict injury nor prevent missed injuries. *J Am Coll Surg* 1998 Jun;186(6):641-4.
<http://www.ncbi.nlm.nih.gov/pubmed/9632150>
21. Lucarelli G, Ditunno P, Bettocchi C, et al. Delayed relief of ureteral obstruction is implicated in the long-term development of renal damage and arterial hypertension in patients with unilateral ureteral injury. *J Urol* 2013 Mar;189(3):960-5.
<http://www.ncbi.nlm.nih.gov/pubmed/23017525>
22. Smith TG, Coburn M. Damage Control Maneuvers for Urologic Trauma. *Urol Clin N Am* 2013 Aug;40:343-350.
<http://www.ncbi.nlm.nih.gov/pubmed/23905932>
23. Koukouras D, Petsas T, Liatsikos E, et al. Percutaneous minimally invasive management of iatrogenic ureteral injuries. *J Endourol* 2010 Dec;24(12):1921-7.
<http://www.ncbi.nlm.nih.gov/pubmed/20964484>
24. De Cicco C, Ussia A, Koninckx PR. Laparoscopic ureteral repair in gynaecological surgery. *Curr Opin Obstet Gynecol* 2011 Aug;23(4):296-300.
<http://www.ncbi.nlm.nih.gov/pubmed/21734501>
25. Chung BI, Hamawy KJ, Zinman LN, et al. The use of bowel for ureteral replacement for complex ureteral reconstruction: long-term results. *J Urol* 2006 Jan;175(1):179-83;discussion 183-4.
<http://www.ncbi.nlm.nih.gov/pubmed/16406903>
26. Armatys SA, Mellon MJ, Beck SD, et al. Use of ileum as ureteral replacement in urological reconstruction. *J Urol* 2009 Jan;181(1):177-81.
<http://www.ncbi.nlm.nih.gov/pubmed/19013597>
27. Meng MV, Freise CE, Stoller ML. Expanded experience with laparoscopic nephrectomy and autotransplantation for severe ureteral injury. *J Urol* 2003 Apr;169(4):1363-7.
<http://www.ncbi.nlm.nih.gov/pubmed/12629362>

4. BLADDER TRAUMA

4.1 Background, incidence and aetiology

4.1.1 External (non-iatrogenic) trauma

Motor vehicle traffic collisions are the most common cause of bladder rupture by blunt trauma (1,2). Falls, industrial trauma/pelvic crush injuries and blows to the lower abdomen are other important causes (1,3). 60-90% of patients with bladder injuries caused by blunt trauma have associated pelvic fractures (1,3), and 44% of patients with bladder injuries have at least one other intra-abdominal injury (4). According to the US National Trauma Data Bank, pelvic fractures are associated with bladder injuries in only 3.6% of cases (2). The majority of ruptures are extraperitoneal, followed by intraperitoneal ruptures and combined intra- and extra-peritoneal ruptures (1,4). A combination of bladder and urethral injury is present in about 15% of cases (1).

Intraperitoneal ruptures are caused by a sudden rise in intravesical pressure, secondary to a blow to the pelvis or lower abdomen. Since the bladder dome is the weakest and most mobile point of the bladder, ruptures will usually occur at this site, resulting in disruption of the peritoneal surface and concomitant urinary extravasation (1).

Extraperitoneal ruptures are almost always associated with pelvic fractures (3). The bladder injury is usually caused by distortion of the pelvic ring, with shearing of the anterolateral bladder wall near the bladder base (at its fascial attachments), or by a 'counter-coup' that bursts opposite the fracture site. Occasionally, the bladder is directly perforated by a sharp bony fragment (1,5). Penetrating bladder injuries, mainly gunshot wounds, are rare in the civilian setting (6).

4.1.2 Iatrogenic trauma

The bladder is the urological organ that most often suffers iatrogenic injury (7). Iatrogenic bladder trauma is defined as a full-thickness laceration. Table 4.1 shows the incidence of bladder perforation during various procedures.

Table 4.1: Incidence of bladder perforation during various procedures

| Procedure | Percentage (%) |
|--|----------------|
| <i>External</i> | |
| <i>Obstetrics</i> | |
| Caesarean delivery (8,9) | 0.0016-0.94 |
| <i>Gynaecology</i> | |
| Laparoscopic sterilization (1) | 0.02 |
| Diagnostic laparoscopy (1) | 0.01 |
| Laparoscopic hysterectomy (10,11) (benign) | 0.5-2.0 |
| Vaginal hysterectomy (10,11) (benign) | 0.44-6.3 |
| Abdominal hysterectomy (10,11) (benign) | 0.73-2.5 |
| <i>General surgery</i> | |
| Inguinal canal surgery (1,12) | 0.08-0.3 |
| Tunnelling of synthetic bypass grafts (13) | Case reports |
| <i>Urology</i> | |
| Retropubic male sling (14) | 8.0-50 |
| Laparoscopic sacrocolpopexy (15) | 1.9 |
| Burch colposuspension (16,17) | 1.0-1.2 |
| Synthetic midurethral slings (all) (16,17) | 6.0-6.6 |
| Transobturator route (16,18) | 0-2.4 |
| Retropubic route (16,18) | 3.2-8.5 |
| Pubovaginal sling (16) | 2.8 |
| Transvaginal mesh surgery (19,20) | 1.5-3.5 |
| Anterior colporrhaphy (19) | 0.5 |
| <i>Internal</i> | |
| TURB (21,22) | 3.5-58 |
| TURP (1) | 0.01 |
| Cystography (23) | Case reports |

TURB = transurethral resection of the bladder; TURP = transurethral resection of the prostate.

4.1.2.1 External iatrogenic bladder trauma

External iatrogenic bladder trauma occurs most often during obstetric and gynaecological procedures, followed by general surgical and urological interventions (7).

4.1.2.2 Internal iatrogenic bladder trauma

Internal iatrogenic bladder trauma mainly occurs during transurethral resection of the bladder (TURB) for the treatment of tumours. Large perforations requiring intervention are rare (0.16-0.57%) (24). Extraperitoneal perforations are more frequent than intraperitoneal ones.

An iatrogenic foreign body inside the bladder can be caused by:

- failure of the resectoscope, ureteric stents or bladder catheters;
- forgotten pieces of surgical gauze, sutures, or staples used in pelvic procedures (25,26);
- an unrecognized perforation; or erosion of mesh for urinary incontinence or pelvic organ prolapse (25).

4.2 Risk factors

Since individuals under the influence of alcohol are more likely to have both a distended bladder and a motor vehicle accident, driving after drinking alcohol is a risk factor for bladder injury (27). A full bladder is a risk factor for intraperitoneal ruptures (1,28).

The highest risk of bladder injury in pelvic fracture was found in disruptions of the pelvic circle with displacement > 1 cm, diastasis of the pubic symphysis > 1 cm and fractures of the rami pubis (2,29). An isolated acetabular fracture is not likely to be associated with bladder injury (29).

Risk factors for iatrogenic bladder trauma are shown in Table 4.2.

Table 4.2: Risk factors for iatrogenic bladder trauma associated with various procedures

| Procedure | Risk factors |
|--------------------------------------|---|
| Caesarean delivery (8,9) | Previous Caesarean delivery |
| | Previous pelvic surgery |
| | Presence of labour |
| | Station of presenting foetal part $\geq + 1$ |
| | Foetal weight > 4 kg |
| Hysterectomy (11,30) | Malignancy |
| | Endometriosis |
| | Prior pelvic surgery |
| | Concomitant anti-incontinence or pelvic organ prolapse surgery |
| General surgery (7) | Malignancy |
| | Diverticulitis |
| | Inflammatory bowel disease |
| Midurethral sling operations (16,31) | Retropubic route |
| | Previous Caesarean delivery |
| | Previous colposuspension |
| | BMI < 30 kg/m ² |
| | Rectocele |
| | Procedures under local anaesthesia |
| TURB (24,32) | Inexperienced surgeon |
| | Tumour size |
| | Elderly patients |
| | Pretreated bladder (previous TURB, intravesical instillation, radiotherapy) |
| | Tumour location at bladder dome or in diverticulum |

BMI = body mass index; TURB = transurethral resection of the bladder.

4.3 Clinical signs and symptoms

4.3.1 External trauma

The clinical presentation of a bladder injury can be distorted by associated pelvic fracture, visceral and/or

vascular injuries (1). The cardinal sign of bladder injury is visible haematuria, present in up to 95% of patients (1,3). The presence of bladder injury is strongly correlated with a combination of pelvic fracture and visible haematuria (34). Thus, the combination of pelvic fracture and visible haematuria is an absolute indication for further bladder imaging (1,33).

Approximately 5-15% of patients with bladder rupture only have non-visible haematuria (29). Existing data do not support lower urinary tract imaging in all patients with pelvic fracture or non-visible haematuria alone. In visible haematuria without pelvic fracture, non-visible haematuria with pelvic fracture and isolated non-visible haematuria, the decision for further imaging should be based on the presence of other clinical signs and symptoms and the site of maximal trauma (1).

Other signs and symptoms include:

- Abdominal tenderness (up to 97%) (3), an inability to void, bruises over the suprapubic region, and abdominal distension in urinary ascites (1,28).
- Extravasation of urine may result in swelling in the perineum, scrotum (through the inguinal canal), and thighs, as well as along the anterior abdominal wall within the potential space between the transversalis fascia and the parietal peritoneum (1).
- In intraperitoneal rupture, reabsorption of urea nitrogen and creatinine through the peritoneal cavity causes uraemia and elevated creatinine levels (1).
- In penetrating abdominal trauma, location of entrance and exit wounds at the lower abdomen, perineum or buttocks should raise suspicion of bladder injury (6,28).
- Severe bladder injuries may be accompanied with soft tissue avulsion of the lower abdominal wall and/or perineum, as well as by bladder tissue loss due to trauma or infection (34).

4.3.1.1 *Caution in case of urinary retention and/or urethral blood loss*

In this situation, a (concomitant) urethral injury must be suspected and retrograde urethrography must be performed to assess the integrity of the urethra before further manipulation of the urethra (e.g. urinary catheter for a cystography) (1,35).

4.3.2 **Iatrogenic trauma**

4.3.2.1 *Peri-operative: external iatrogenic bladder trauma*

Direct inspection is the most reliable method of assessing bladder integrity. Suggestive signs are extravasation of urine, visible laceration, clear fluid in the surgical field, appearance of the bladder catheter, and blood and/or gas in the urine bag during laparoscopy (1,8). Intravesical instillation of methylene blue may be helpful (8,30). If bladder perforation is present, the integrity of the ureteric orifices should be checked (1,30).

4.3.2.2 *Peri-operative: internal iatrogenic bladder trauma*

Bladder perforation is suggested by fatty tissue, a dark space between detrusor muscle fibres, or the visualization of bowel (21). Signs of major perforation are the inability to distend the bladder, a low return of irrigation fluid, and abdominal distension (36,37).

4.3.2.3 *Post-operative: unrecognized bladder injury*

Clinical signs and symptoms include haematuria, lower abdominal pain, abdominal distension, ileus, peritonitis, sepsis, urine leakage from the wound, decreased urinary output, and increased serum creatinine (1,38).

4.3.3 **Intravesical foreign body**

Symptoms of an intravesical foreign body include dysuria, recurrent urinary tract infection, frequency, urgency, haematuria, and perineal/pelvic pain (25). Bladder calculi usually develop once the foreign body has been present for longer than 3 months (25,39).

4.4 **Imaging**

4.4.1 **Cystography (conventional or CT)**

Cystography is the preferred diagnostic modality for non-iatrogenic bladder injury and for a suspected iatrogenic bladder injury in the post-operative setting (5,28). Both conventional and CT cystography have a comparable sensitivity of 90-95% and specificity of 100% (3,40). However, CT cystography has the advantage of being able to diagnose other injuries or causes of abdominal pain (1,41).

CT or conventional cystography must be performed using slow retrograde filling of the bladder with a minimum of 350 mL of dilute contrast material (5). A plain film, a complete filling film and a post-drainage film are the absolute minimum films required during conventional cystography (5). With CT cystography, 3D-reconstruction is helpful in defining the location of the bladder rupture and makes a post-drainage series unnecessary (42).

With intraperitoneal extravasation, free contrast medium is visualized in the abdomen, highlighting bowel loops and/or outlining abdominal viscera such as the liver (1,38).

Extraperitoneal bladder injury is associated with flame-shaped areas of contrast extravasation in the perivesical soft tissues (1).

4.4.2 **Cystoscopy**

Cystoscopy is the preferred method to detect intra-operative bladder injuries. Routine post-operative cystoscopy after gynaecological procedures remains controversial, but it is recommended for all procedures where bladder injury is suspected (30). Vakili et al. reported that 64.7% of bladder injuries during hysterectomy were not detected before cystoscopy and advised the routine use of cystoscopy after hysterectomy and every major gynaecological procedure (11).

Cystoscopy is recommended to detect any perforation of the bladder (or urethra) following minimally invasive, synthetic, suburethral sling operations by the retropubic route (17,43). During cystoscopy, the bladder must be adequately distended and a 70° optic or flexible cystoscope must be used to inspect areas close to the bladder neck (25,43). The use of routine cystoscopy for insertion by obturator route is controversial because bladder injuries are rare but not impossible (17,43). Cystoscopy after transvaginal mesh procedures is preferable, but not mandatory (44).

Cystoscopy with adequate bladder distension may directly visualize the laceration. Cystoscopy can correlate the lesion with the position of the trigone and ureteral orifices (38). A lack of bladder distension during cystoscopy suggests a large perforation.

Cystoscopy is the preferred examination method if there is a suspected iatrogenic foreign body (26,39).

4.4.3 **Excretory phase of CT or IVP**

Passive bladder filling by clamping the urinary catheter during the excretory phase of CT or IVP is not sufficient to exclude bladder injury (1,5). However, the finding of contrast extravasation during the excretory phase is suggestive of bladder injury.

4.4.4 **Ultrasound**

Intraperitoneal fluid or an extraperitoneal collection suggests intraperitoneal or extraperitoneal perforation, respectively. Ultrasound alone is insufficient in the diagnosis of bladder trauma (1).

4.5 **Treatment**

If operative bladder repair is performed, the preferred method is two-layer vesicorrhaphy (mucosa-detrusor) with absorbable sutures (1,30).

4.5.1 **External trauma**

4.5.1.1 *Blunt trauma: extraperitoneal rupture*

Most patients with uncomplicated extraperitoneal rupture can be managed safely by catheter drainage alone, even in the presence of extensive retroperitoneal or scrotal extravasation (1,28). However, surgical intervention will be necessary for bladder neck involvement, the presence of bone fragments in the bladder wall, concomitant rectal injury or entrapment of the bladder wall (1,28).

In orthopaedic surgery, there is an increasing trend to treat pelvic ring fractures with open stabilization and internal fixation with osteosynthetic material. In order to prevent infection of the osteosynthetic material, there is increasing interest in suturing an extraperitoneal rupture (1,3). In surgical exploration for other injuries, an extraperitoneal rupture should be sutured concomitantly to reduce infective complications (especially paravesical abscess) (3,4).

4.5.1.2 *Blunt trauma: intraperitoneal rupture*

Intraperitoneal ruptures occurring after blunt trauma should always be managed by formal surgical repair (1,28) because intraperitoneal extravasation of urine can lead to peritonitis, intra-abdominal sepsis and death (4).

Abdominal organs should be inspected for possible associated injuries; an urinoma must be drained if detected. If there are no other intra-abdominal injuries, laparoscopic suturing of the intraperitoneal rupture is possible (3).

4.5.1.3 *Penetrating injuries*

All bladder perforations resulting from penetrating trauma should undergo emergency exploration, debridement of devitalized bladder muscle and subsequent bladder repair (6,28). A midline exploratory cystotomy is

advised to inspect the bladder wall and distal ureters (1,6). In gunshot wounds, there is a strong association with intestinal and rectal injuries, requiring faecal diversion (6). Most gunshot wounds are associated with two transmural injuries (entry and exit wounds) and the bladder should be carefully checked for two lesions (6).

4.5.1.4 Bladder injuries with avulsion of lower abdominal wall or perineum and/or bladder tissue loss

In these cases, direct closure of the traumatized bladder will lead to excessive tension, resulting in ischaemia and eventually breakdown of the repair. A bladder wall substitute is needed to repair the bladder defects and to restore the lower abdominal wall or perineum. A pedicled vastus lateralis myocutaneous flap has been used in post-traumatic bladder reconstruction and soft-tissue coverage for the lower abdomen or perineum (34).

4.5.2 Iatrogenic injuries

Perforations recognized intra-operatively are primarily closed. For bladder injuries not recognized during surgery or for internal injuries, a distinction must be made between intraperitoneal and extraperitoneal injuries.

For intraperitoneal injuries, the standard of care is surgical exploration with repair (1,38). In selected cases (in the absence of peritonitis or ileus), conservative management with continuous bladder drainage and antibiotic prophylaxis may be offered (1,38). As well as conservative treatment, placement of an intraperitoneal drain has been advocated, especially when the lesion is larger (37,45). If surgical exploration is performed after transurethral resection of the bladder (TURB), the bowel must be meticulously inspected to rule out concomitant injury (24).

For extraperitoneal injuries, conservative treatment with bladder drainage and antibiotic prophylaxis is advised (1,32). Large extraperitoneal perforations complicated by symptomatic extravescical collections require drainage, with or without closure of the perforation (46).

If perforation occurs during TURB, immediate intravesical instillation with chemotherapeutic agents should not be performed (47). If bladder perforation is encountered during midurethral sling or transvaginal mesh procedures, sling re-insertion and urethral catheterization (1-2 days) should be performed (31).

4.5.3 Intravesical foreign body

For perforated or eroded meshes, the intravesical portion must be removed by open cystotomy or endoscopically (39,48). The choice depends on the surgeon's level of experience and mesh location (39,48). For other types of foreign body, cystoscopic removal is performed but if this fails cystotomy is performed (26).

4.5.4 Post-operative management

Post-operative continuous bladder drainage is required to allow the bladder to heal and to prevent elevated intravesical pressure and disruption of the suture line (30). For external trauma and external iatrogenic bladder injuries, the bladder catheter is maintained for 7-14 days, depending on the extent of laceration (1,30). Cystography upon removal of the catheter is advised. In contrast extravasation, continuous bladder drainage is maintained for at least 1 week and until cystography no longer shows extravasation (1,30). For conservatively treated internal iatrogenic bladder injuries, the catheter duration should be 5 days for extraperitoneal and 7 days for intraperitoneal perforations (32,49).

4.6 Statements and recommendations

| Statements | LE |
|--|----|
| Extraperitoneal bladder perforations are more common than intraperitoneal perforations. | 3 |
| Risk of bladder perforation during midurethral sling operations for stress urinary incontinence is lower for the obturator route compared to the retropubic route. | 1a |
| The combination of pelvic fracture and visible haematuria is highly suggestive of bladder injury. | 3 |

| Recommendations | GR |
|---|----|
| Cystography is the preferred diagnostic modality for non-iatrogenic bladder injury, and in suspected, iatrogenic, post-operative, bladder injury. | B |
| Cystography (conventional or CT imaging) is required in the presence of visible haematuria and pelvic fracture. | B |
| Cystography should be performed with gentle filling of the bladder with at least 350 mL of dilute contrast. Passive bladder filling by clamping the catheter during the excretory phase of CT or IVP is insufficient for diagnosis. | B |
| Cystoscopy is recommended after suburethral sling operations via the retropubic route and major gynaecological operations. It is optional after any other type of sling procedure or transvaginal mesh procedure. | B |
| In the absence of bladder neck involvement and/or associated injuries that require surgical intervention, extraperitoneal bladder ruptures caused by blunt trauma are managed conservatively. | B |
| Intraperitoneal bladder ruptures by blunt trauma, and any type of bladder injury by penetrating trauma, must be managed by emergency surgical exploration and repair. | B |
| Conservative management is an option for small, uncomplicated, iatrogenic intraperitoneal bladder perforations. | C |

4.7 References

- Gomez RG, Ceballos L, Coburn M, et al. Consensus statement on bladder injuries. *BJU Int* 2004 Jul;94(1):27-32.
<http://www.ncbi.nlm.nih.gov/pubmed/15217426>
- Bjurlin MA, Fantus RJ, Mellett MM, et al. Genitourinary injuries in pelvic fracture morbidity and mortality using the National Trauma Data Bank. *J Trauma* 2009 Nov;67(5):1033-9.
<http://www.ncbi.nlm.nih.gov/pubmed/19901665>
- Wirth GJ, Peter R, Poletti PA, et al. Advances in the management of blunt traumatic bladder rupture: experience with 36 cases. *BJU Int* 2010 Nov;106(9):1344-9.
<http://www.ncbi.nlm.nih.gov/pubmed/20438556>
- Deibert CM, Spencer BA. The association between operative repair of bladder injury and improved survival: results from the National Trauma Data Bank. *J Urol* 2011 Jul;186(1):151-5.
<http://www.ncbi.nlm.nih.gov/pubmed/21575961>
- Ramchandani P, Buckler PM. Imaging of genitourinary trauma. *AJR Am J Roentgenol* 2009 Jun;192(6):1514-23.
<http://www.ncbi.nlm.nih.gov/pubmed/19457813>
- Cinman NM, McAninch JW, Porten SP, et al. Gunshot wounds to the lower urinary tract: a single-institution experience. *J Trauma Acute Care Surg* 2013 Mar;74(3):725-30.
<http://www.ncbi.nlm.nih.gov/pubmed/23425728>
- Armenakas NA, Pareek G, Fracchia JA. Iatrogenic bladder perforations: longterm followup of 65 patients. *J Am Coll Surg* 2004 Jan;198(1):78-82.
<http://www.ncbi.nlm.nih.gov/pubmed/14698314>
- Gungorduk K, Asicioglu O, Celikkol O, et al. Iatrogenic bladder injuries during caesarean delivery: a case control study. *J Obstet Gynaecol* 2010;30(7):667-70.
<http://www.ncbi.nlm.nih.gov/pubmed/20925606>
- Rahman MS, Gasem T, Al Suleiman SA, et al. Bladder injuries during cesarean section in a University Hospital: a 25-year review. *Arch Gynecol Obstet* 2009 Mar;279(3):349-52.
<http://www.ncbi.nlm.nih.gov/pubmed/18648828>
- Donnez O, Jadoul P, Squifflet J, et al. A series of 3190 laparoscopic hysterectomies for benign disease from 1990 to 2006: evaluation of complications compared with vaginal and abdominal procedures. *BJOG* 2009 Mar;116(4):492-500.
<http://www.ncbi.nlm.nih.gov/pubmed/19016683>
- Vakili B, Chesson RR, Kyle BL, et al. The incidence of urinary tract injury during hysterectomy: a prospective analysis based on universal cystoscopy. *Am J Obstet Gynecol* 2005 May;192(5):1599-604.
<http://www.ncbi.nlm.nih.gov/pubmed/15902164>
- Aloi IP, Lais A, Caione P. Bladder injuries following inguinal canal surgery in infants. *Pediatr Surg Int* 2010 Dec;26(12):1207-10.
<http://www.ncbi.nlm.nih.gov/pubmed/20820790>
- Nakamura LY, Ferrigni RG, Stone WM, et al. Urinary bladder injuries during vascular surgery. *J Vasc Surg* 2010 Aug;52(2):453-5.
<http://www.ncbi.nlm.nih.gov/pubmed/20541350>

14. Welk BK, Herschorn S. Are male slings for post-prostatectomy incontinence a valid option? *Curr Opin Urol* 2010 Nov;20(6):465-70.
<http://www.ncbi.nlm.nih.gov/pubmed/20838219>
15. Maher CF, Feiner B, DeCuyper EM, et al. Laparoscopic sacral colpopexy versus total vaginal mesh for vaginal vault prolapse: a randomized trial. *Am J Obstet Gynecol* 2011 Apr;204(4):360.e1-7.
<http://www.ncbi.nlm.nih.gov/pubmed/21306698>
16. Novara G, Artibani W, Barber MD, et al. Updated systematic review and meta-analysis of the comparative data on colposuspensions, pubovaginal slings, and midurethral tapes in the surgical treatment of female stress urinary incontinence. *Eur Urol* 2010 Aug;58(2):218-38.
<http://www.ncbi.nlm.nih.gov/pubmed/20434257>
17. Ogah J, Cody DJ, Rogerson L. Minimally invasive synthetic suburethral sling operations for stress urinary incontinence in women: a short version Cochrane review. *Neurourol Urodyn* 2011 Mar;30(3):284-91.
<http://www.ncbi.nlm.nih.gov/pubmed/21412819>
18. Long CY, Hsu CS, Wu MP, et al. Comparison of tension-free vaginal tape and transobturator tape procedure for the treatment of stress urinary incontinence. *Curr Opin Obstet Gynecol* 2009 Aug;21(4):342-7.
<http://www.ncbi.nlm.nih.gov/pubmed/19528799>
19. Altman D, Väyrynen T, Engh ME, et al. Anterior colporrhaphy versus transvaginal mesh for pelvic organ prolapse. *N Engl J Med* 2011 May;364(19):1826-36.
<http://www.ncbi.nlm.nih.gov/pubmed/21561348>
20. Huang WC, Lin TY, Lau HH, et al. Outcome of transvaginal pelvic reconstructive surgery with Prolift after a median of 2 years' follow-up. *Int Urogynecol J* 2011 Feb;22(2):197-203.
<http://www.ncbi.nlm.nih.gov/pubmed/20821308>
21. Balbay MD, Cimentepe E, Unsal A, et al. The actual incidence of bladder perforation following transurethral bladder surgery. *J Urol* 2005 Dec;174(6):2260-2, discussion 2262-3.
<http://www.ncbi.nlm.nih.gov/pubmed/1628079423>
22. Nieder AM, Meinbach DS, Kim SS, et al. Transurethral bladder tumor resection: intraoperative and postoperative complications in a residency setting. *J Urol* 2005 Dec;174(6):2307-9.
<http://www.ncbi.nlm.nih.gov/pubmed/16280830>
23. Khavari R, Bayne AP, Roth DR. A report of an iatrogenic bladder rupture in a normal healthy child during voiding cystourethrography. *Urology* 2010 Mar;75(3):684-6.
<http://www.ncbi.nlm.nih.gov/pubmed/19716588>
24. Golan S, Baniel J, Lask D, et al. Transurethral resection of bladder tumour complicated by perforation requiring open surgical repair - clinical characteristics and oncological outcomes. *BJU Int* 2011 Apr;107(7):1065-8.
<http://www.ncbi.nlm.nih.gov/pubmed/20860654>
25. Frenkl TL, Rackley RR, Vasavada SP, et al. Management of iatrogenic foreign bodies of the bladder and urethra following pelvic floor surgery. *Neurourol Urodyn* 2008;27(6):491-5.
<http://www.ncbi.nlm.nih.gov/pubmed/18537142>
26. Rafique M. Intravesical foreign bodies: review and current management strategies. *Urol J* 2008 Fall;5(4):223-31.
<http://www.ncbi.nlm.nih.gov/pubmed/19101894>
27. Dreitlein DA, Suner S, Basler J. Genitourinary trauma. *Emerg Med Clin North Am* 2001 Aug;19(3):569-90.
<http://www.ncbi.nlm.nih.gov/pubmed/1155427629>
28. Tonkin JB, Tisdale BE, Jordan GH. Assessment and initial management of urologic trauma. *Med Clin North Am* 2011 Jan;95(1):245-51.
<http://www.ncbi.nlm.nih.gov/pubmed/21095427>
29. Avey G, Blackmore CC, Wessells H, et al. Radiographic and clinical predictors of bladder rupture in blunt trauma patients with pelvic fracture. *Acad Radiol* 2006 May;13(5):573-9.
<http://www.ncbi.nlm.nih.gov/pubmed/16627198>
30. Wohlrab KJ, Sung VW, Rardin CR. Management of laparoscopic bladder injuries. *J Minim Invasive Gynecol* 2011 Jan-Feb;18(1):4-8.
<http://www.ncbi.nlm.nih.gov/pubmed/21195952>
31. Stav K, Dwyer PL, Rosamilia A, et al. Risk factors for trocar injury to the bladder during mid urethral sling procedures. *J Urol* 2009 Jul;182(1):174-9.
<http://www.ncbi.nlm.nih.gov/pubmed/19450824>
32. El Hayek OR, Coelho RF, Dall'oglio MF, et al. Evaluation of the incidence of bladder perforation after transurethral bladder tumor resection in a residency setting. *J Endourol* 2009 Jul;23(7):1183-6.
<http://www.ncbi.nlm.nih.gov/pubmed/19530900>

33. Morey AF, Iverson AJ, Swan A, et al. Bladder rupture after blunt trauma: guidelines for diagnostic imaging. *J Trauma* 2001 Oct;51(4):683-6.
<http://www.ncbi.nlm.nih.gov/pubmed/11586159>
34. Wu CW, Lin CH, Lin CH. One-stage posttraumatic bladder reconstruction and soft-tissue coverage of the lower abdomen or perineum. *Ann Plast Surg* 2010 Jan;64(1):65-8.
<http://www.ncbi.nlm.nih.gov/pubmed/20023456>
35. Gallentine ML, Morey AF. Imaging of the male urethra for stricture disease. *Urol Clin North Am* 2002 May;29(2):361-72.
<http://www.ncbi.nlm.nih.gov/pubmed/12371227>
36. Dorotta I, Basali A, Ritchey M, et al. Transurethral resection syndrome after bladder perforation. *Anesth Analg* 2003 Nov;97(5):1536-8.
<http://www.ncbi.nlm.nih.gov/pubmed/14570683>
37. Manikandan R, Lynch N, Grills RJ. Percutaneous peritoneal drainage for intraperitoneal bladder perforations during transurethral resection of bladder tumors. *J Endourol* 2003 Dec;17(10):945-7.
<http://www.ncbi.nlm.nih.gov/pubmed/14744369>
38. Alperin M, Mantia-Smaldone G, Sagan ER. Conservative management of postoperatively diagnosed cystotomy. *Urology* 2009 May;73(5):1163.e17-9.
<http://www.ncbi.nlm.nih.gov/pubmed/18514295>
39. Foley C, Patki P, Boustead G. Unrecognized bladder perforation with mid-urethral slings. *BJU Int* 2010 Nov;106(10):1514-8.
<http://www.ncbi.nlm.nih.gov/pubmed/20518762>
40. Quagliano PV, Delair SM, Malhotra AK. Diagnosis of blunt bladder injury: A prospective comparative study of computed tomography cystography and conventional retrograde cystography. *J Trauma* 2006 Aug;61(2):410-21;discussion 421-2.
<http://www.ncbi.nlm.nih.gov/pubmed/16917459>
41. Shenfeld OZ, Gnessin E. Management of urogenital trauma: state of the art. *Curr Opin Urol* 2011 Nov;21(6):449-54.
<http://www.ncbi.nlm.nih.gov/pubmed/21897259>
42. Chan DP, Abujudeh HH, Cushing GL Jr, et al. CT cystography with multiplanar reformation for suspected bladder rupture: experience in 234 cases. *AJR Am J Roentgenol* 2006 Nov;187(5):1296-302.
<http://www.ncbi.nlm.nih.gov/pubmed/17056919>
43. Daneshgari F, Kong W, Swartz M. Complications of mid urethral slings: important outcomes for future clinical trials. *J Urol* 2008 Nov;180(5):1890-7.
<http://www.ncbi.nlm.nih.gov/pubmed/18801499>
44. Bekker MD, Bevers RF, Elzevier HW. Transurethral and suprapubic mesh resection after Prolift bladder perforation: a case report. *Int Urogynecol J* 2010 Oct;21(10):1301-3.
<http://www.ncbi.nlm.nih.gov/pubmed/20204325>
45. Pansadoro A, Franco G, Laurenti C, et al. Conservative treatment of intraperitoneal bladder perforation during transurethral resection of bladder tumor. *Urology* 2002 Oct;60(4):682-4.
<http://www.ncbi.nlm.nih.gov/pubmed/12385934>
46. Traxer O, Pasqui F, Gattegno B, et al. Technique and complications of transurethral surgery for bladder tumours. *BJU Int* 2004 Sep;94(4):492-6.
<http://www.ncbi.nlm.nih.gov/pubmed/15329099>
47. Babjuk M, Oosterlinck W, Sylvester R, et al. EAU guidelines on non-muscle-invasive urothelial carcinoma of the bladder, the 2011 update. *Eur Urol* 2011 Jun;59(6):997-1008.
<http://www.ncbi.nlm.nih.gov/pubmed/21458150>
48. Araco F, Gravante G, Piccione E. Bladder erosion after 2 years from cystocele repair with type I polypropylene mesh. *Int Urogynecol J Pelvic Floor Dysfunct* 2009 Jun;20(6):731-3.
<http://www.ncbi.nlm.nih.gov/pubmed/18815720>
49. Collado A, Chechile GE, Salvador J, et al. Early complications of endoscopic treatment for superficial bladder tumors. *J Urol* 2000 Nov;164(5):1529-32.
<http://www.ncbi.nlm.nih.gov/pubmed/11025697>

5. URETHRAL TRAUMA

5.1 Anterior urethral injuries

Different causes of anterior injuries (1) are depicted in Table 5.1. Anterior urethral injuries are mainly caused by blunt trauma (1-3), with the bulbar urethra being the most common site injured (3,4). In these bulbar injuries, which are mostly 'straddle injuries' or kicks in the perineum, the bulb is compressed against the pubic symphysis, resulting in rupture of the urethra at this site (5). Penetrating injuries of the penile or bulbar urethra are rare and usually caused by gunshot wounds (5-10). Depending on the affected segment, penetrating injuries are associated with penile, testicular and/or pelvic injuries (7,10).

Insertion of foreign bodies is another rare cause of anterior injury. It is usually a result of autoerotic stimulation or may be associated with psychiatric disorders (6). Penile fractures account for 10-20% of anterior injuries (6). In up to one-third of cases, the tear extends into the corpus spongiosum and urethra (11). Urethral instrumentation is by far the most common cause of urethral trauma in the Western world and can affect all segments of the anterior urethra (12,13).

Table 5.1: Aetiology of urethral injury

| Cause | Example |
|---------------------|--|
| Blunt trauma | Vehicular accidents Fall astride ('straddle') e.g. on bicycle, fences, inspection covers Kicks in the perineum |
| Sexual intercourse | Penile fractures Urethral intraluminal stimulation |
| Penetrating trauma | Gunshot wounds Stab wounds Dog bites External impalement Penile amputations |
| Constriction bands | Paraplegia |
| Iatrogenic injuries | Endoscopic instruments Urethral catheters/dilators |

5.2 Posterior urethral injuries (in males)

Injuries to the posterior urethra are most often related to pelvic fractures (about 72%) (12,13), which themselves are usually caused by motor vehicle accidents (14-16). Iatrogenic posterior injuries, due to irradiation or surgery to the prostate, are an increasing problem (12,13), but appear to be less common than previously believed (3-25%) (1).

During crush or deceleration impact injury, the severe shearing forces needed to fracture the pelvis are transmitted to the attachments of the perineal membrane and puboprostatic ligaments (17). Most posterior injuries therefore occur at the bulbomembranous junction, just distal of the external urethral sphincter (18,19). Direct transection of the urethra by a bony fragment is rare (14).

Surgically, these injuries must be divided into either partial or complete ruptures. In complete ruptures, there is a gap between the disrupted ends of the urethra. The dismembered ends of the urethra retract and fibrous tissue fills the space between them (14). There is no urethral wall in the scarred space and any lumen represents merely a fistulous tract between the urethral stumps (14). Injury to the posterior urethra exclusively occurs in pelvic fractures with disruption of the pelvic ring (15). The highest risk of urethral injury is in straddle fractures with a concomitant diastasis of the sacroiliac joint, followed by straddle fracture alone, and a Malgaigne fracture (20). Displaced fractures of the inferomedial pubic bone and pubic symphysis diastasis, together with their degree of displacement, are independent predictors of urethral injury (16). Injuries of the bladder neck and prostate are rare (21). They mostly occur at the anterior midline of both the bladder neck and prostatic urethra. More rare is a complete transection of the bladder neck or an avulsion of the anterior part of the prostate (21).

Penetrating injuries of the pelvis, perineum or buttocks (mainly gunshot wounds) can also cause damage to the posterior urethra, but are extremely rare (22). There is a high probability of associated injuries (80-90%), mainly intra-abdominal (22,23).

Although urethral injuries themselves are not directly life-threatening (1,15), they are closely associated with pelvic fractures. Since pelvic fractures with urethral injuries are more likely to be associated with

concomitant injuries (particularly those of the thorax, abdomen and spine), these patients have a substantial early morbidity and mortality (13.99%) (15,16).

Posterior urethral injuries can also result in significant delayed morbidity. Strictures, incontinence and erectile dysfunction (ED) are well-recognized associated problems that interfere with the quality of life. It is therefore important to diagnose and treat these injuries efficiently to reduce the severity and duration of such complications (24).

Erectile dysfunction occurs in approximately 45% of patients after traumatic posterior urethral rupture (24). Strong predictors for ED are diastasis of the pubic symphysis (24-26), lateral displacement of the prostate (24,27) and a long urethral gap (> 2cm) (24). Other factors that may predict ED are bilateral pubic rami fractures and Malgaigne's fracture (24). The severity of the initial injury is also important: a 1-point increase in Injury Severity Score is associated with a 2% increase in the risk of ED (28).

Erectile dysfunction is the most common neurogenic injury and is caused by damage to the cavernous nerves found at the prostatomembranous urethra behind the symphysis pubis (24,25). Associated vasculogenic ED is common (25). The spontaneous return of potency usually occurs during the first year, but may take up to 2 years after injury (26). Thus, the preferable timing for assessing definitive sexual function and deciding on further therapy (e.g. implantation of erectile prosthesis) is 2 years after the initial trauma (24).

5.3 Urethral injuries in females

Urethral injuries are very rare in females because of the short length of the female urethra, its mobility and the lack of attachments to the pubic bone (2,5). Pelvic fractures are the main aetiology, in which the urethra is directly injured by the sharp edges of bony fragments (2). The injury is usually a partial longitudinal tear of the anterior wall (2,6). Complete avulsion is extremely rare (29). In this case, there is often extension in the bladder neck and associated vaginal laceration (2). Urethral injuries in females extending into the bladder neck disrupt the normal continence mechanism (30).

5.4 Diagnosis in males and females

5.4.1 Clinical signs and symptoms

Blood at the meatus is the cardinal sign of urethral injury (14). The absence of it, however, doesn't rule out a urethral injury. Meatal blood loss is present in 98% of posterior injuries and in 75% of anterior injuries (2). The amount of urethral bleeding correlates poorly with the severity of the injury (2).

An inability to void (with a palpable distended bladder) is another classic sign and is often associated with a complete rupture (14). However, it should be noted that an ability to void does not exclude a partial rupture (2); in addition, haematuria and pain on urination may be present. Urinary extravasation and bleeding may result in scrotal, penile and/or perineal swelling and ecchymosis, depending on the location and extent of the trauma (1,6). The presentation of these clinical symptoms may be delayed and may only become apparent more than 1 hour after the initial trauma (14).

A rectal examination may reveal a 'high-riding' prostate, which is a relatively unreliable finding in the acute phase of urethral injury (14,19). This is because the pelvic haematoma associated with pelvic fractures often precludes the adequate palpation of a small prostate, particularly in younger men (2). Rectal examination should always be done to exclude an associated rectal injury (up to 5% of cases) (19,29). Failure to detect a rectal injury will cause significant morbidity and even mortality (19). A rectal injury is suggested by blood on the examination finger and/or a palpable laceration (19). Another sign of urethral injury is difficulty or an inability to pass a urethral catheter (19).

A female urethral injury should be suspected from the combination of a pelvic fracture with blood at the vaginal introitus, vaginal laceration, haematuria, urethrorrhagia, labial swelling and/or urinary retention (2,5,6). Vaginal examination is indicated to assess vaginal lacerations (19).

5.4.2 Further diagnostic techniques

5.4.2.1 Retrograde urethrography

Retrograde urethrography is the standard diagnostic investigation for the acute evaluation of a urethral injury (1). A scout film should first be performed to detect pelvic fractures and foreign bodies, such as bullets (5). A retrograde urethrography is then conducted by injecting 20-30 mL of contrast material while occluding the meatus. Films should be taken in a 30°-oblique position, unless this is not possible because of the severity of the pelvic fractures and associated patient discomfort (1,6). In an unstable patient, retrograde urethrography should be postponed until the patient has been stabilized (2,23).

5.4.2.2 Urethrogram

The urethrogram allows for identification of the site and assessment of the extent of any injury (2,19). Any extravasation outside the urethra is pathognomonic for urethral injury. However, the distinction between a complete and partial rupture is not always clear (14). A typical image for incomplete rupture is extravasation that occurs while the bladder is still filling. A complete rupture is suggested by massive extravasation without bladder filling (14). Based on the findings of retrograde urethrography, the 2004 consensus panel on urethral trauma proposed a new classification (Table 5.2), which is simple and relevant in the treatment of urethral injuries (see later) (1):

Table 5.2: Staging of urethral injuries*

| |
|--|
| Anterior urethra <ul style="list-style-type: none">• Partial disruption• Complete disruption Posterior urethra <ul style="list-style-type: none">• Stretched but intact• Partial disruption• Complete disruption• Complex (involves bladder neck/rectum) |
|--|

*According to the 2004 consensus panel on urethral trauma (1).

5.4.2.3 Ultrasound, CT and MR imaging

In the acute phase, ultrasound (US), CT and MRI are useful to evaluate concomitant injuries (1,6). However, since the patient has to be fully co-operative and must have shown the ability to void (32), it is unlikely to be useful in the acute trauma setting and therefore cannot be generally recommended. It is suitable, however, for guiding the placement of a suprapubic catheter (1).

5.4.2.4 Cystoscopy

Bedside flexible cystoscopy is an option to diagnose (and manage) an acute urethral injury. Cystoscopy can also distinguish between incomplete and complete rupture. It is easy and quick to perform and can be done in a supine position (without the need to reposition the patient on the X-ray table) (1). In addition, it may allow a guidewire to be passed into the bladder for early catheterization (2,34). Flexible cystoscopy is also recommended above retrograde urethrography in suspected penile fracture-associated urethral injury because of the high false-negative rates seen in retrograde urethrography (30,35,36). In females, where the short urethra precludes adequate retrograde urethrography, urethroscopy and vaginoscopy are important adjuncts to the physical examination for the identification and staging of urethral and vaginal injuries (1,2).

5.4.2.5 Summary

Prior to deferred management, the combination of retrograde urethrography and antegrade cystourethrography is standard (1). The location and extent of the obliteration is diagnosed (1). An MRI of the pelvis provides valuable additional information, which can help to determine the most appropriate surgical strategy (1,27). Using MRI, it is possible to estimate the exact length of the urethral gap, the degree and direction of prostatic displacement, the degree and extent of fibrotic tissue and to reveal false paraurethral tracks (27). If the competence of the bladder neck is not clear upon antegrade cystourethrography, suprapubic cystoscopy is advised (1).

5.5 Management

Treatment of urethral injuries is controversial because of the lack of well-conducted clinical trials to provide a high level of evidence.

5.5.1 Anterior urethral injuries

Anterior urethral injuries are usually not associated with other life-threatening injuries (2,6). Treatment decisions are based mainly upon the type of injury (blunt, penile fracture associated or penetrating).

5.5.1.1 Blunt anterior urethral injuries

Blunt anterior urethral injuries are associated with spongiosal contusion, which makes it more difficult to evaluate the limits of urethral debridement in the acute phase. Acute or early urethroplasty is therefore not indicated (1). The therapeutic options in the acute management of an injury consist of suprapubic diversion or (a trial of) early endoscopic realignment with transurethral catheterization (2). Urinary diversion is maintained for

2 and 3 weeks for partial and complete ruptures, respectively (4).

Satisfactory urethral luminal recanalization may occur in up to 68% after partial ruptures, but is rare after complete ruptures (4,37). This finding may possibly be explained by a foreign body reaction to the transurethral catheter, which aggravates the acute and chronic inflammatory reaction, together with the additional damage that occurs during endoscopic realignment due to irrigation and manipulation (4). Subsequent urethroplasty was reported to be more complex after failed early endoscopic realignment (3).

5.5.1.2 *Penile fracture-related anterior urethral injuries*

In order to preserve erectile function, penile fractures require early exploration (5,30,38,39). The strategy consists of closing the tear in the cavernosal tunica albuginea, while the concomitant tear in the urethra is repaired at the same time (38). In these circumstances, there is no substantial urethral tissue loss (40). A small laceration can be repaired by simple closure, while a complete rupture requires spatulation of the disrupted ends and anastomotic repair (38,39).

5.5.1.3 *Penetrating anterior urethral injuries*

Immediate exploration is advised, except when this is precluded by other life-threatening injuries (1). Devitalized tissues should be debrided, although urethral and spongiosal debridement should be kept to a minimum due to the excellent vascularization (10,30). For small lacerations and stab wounds, simple urethral closure might be sufficient (1). Defects up to 2-3 cm in the bulbar urethra, and up to 1.5 cm in the penile urethra, can be treated by spatulation of the urethral ends and primary anastomosis (2,8,10). In the case of larger defects or apparent infection (particularly bite wounds), a staged repair with urethral marsupialization and a suprapubic catheter is needed (8,10). Peri- and post-operative antibiotic treatment is necessary (9).

5.6.1 **Posterior urethral injuries**

5.6.1.1 *Blunt posterior urethral injuries*

In posterior injuries, it is important to distinguish between complete and partial rupture to proceed with treatment. Timing of the intervention is classified as (1,2):

- Immediate: < 48 hours after injury (5.6.1.1.1);
- Delayed primary: 2 days to 2 weeks after injury (5.6.1.1.2);
- Deferred: > 3 months after injury (5.6.1.1.3).

5.6.1.1.1 Immediate management

Although urinary diversion is not essential during the first hours after trauma, many physicians of the trauma team prefer to perform an early urinary diversion for three main reasons (2,14):

- To monitor urinary output, since this is a valuable sign of the haemodynamic condition and the renal function of the patient;
- To treat symptomatic retention if the patient is still conscious;
- To minimize urinary extravasation and its secondary effects, such as infection and fibrosis.

Insertion of a suprapubic catheter is always a good solution in urgent situations (1,30). However, insertion of a suprapubic catheter is not without risk, especially in the unstable trauma patient where the bladder is often displaced by the pelvic haematoma or because of poor bladder filling due to haemodynamic shock or concomitant bladder injury. In these circumstances, an attempt at urethral catheterization can be carried out by experienced hands; the balloon of the Foley catheter should only be inflated if urine flows out.

It is extremely unlikely that the gentle passage of a urethral catheter will do any additional damage (2,6,12-14,40). Although it has been suggested that passing a catheter may convert a partial into a complete tear, there are no convincing data to confirm this. Moreover, there are no data indicating that there is a higher rate of infection or urethral stricture after a single attempt at catheterization (2,14). If there is any difficulty, a suprapubic catheter should be placed under US guidance or direct vision during laparotomy (14).

5.6.1.1.1.1 Partial posterior urethral rupture

Partial tears of the posterior urethra can be managed with a suprapubic or urethral catheter (30). Urethrography should be performed at 2-weekly intervals until healing has occurred (29,41). Injuries may heal without significant scarring or obstruction if managed by diversion alone (30). A residual or subsequent stricture should be managed with:

- Internal urethrotomy if it is short and non-obliterated;
- Anastomotic urethroplasty, if it is long and dense, as is found with complete obliteration or after failed internal urethrotomy (37,42).

5.6.1.1.1.2 Complete posterior urethral rupture

Acute treatment options include:

- Immediate realignment: apposition of the urethral ends over a catheter (5.6.1.1.1.2.1);
- Immediate urethroplasty: suturing of urethral ends (5.6.1.1.1.2.2)

5.6.1.1.1.2.1 Immediate realignment

The aim of realignment is to correct severe distraction injuries rather than to prevent a stricture (30).

The reported benefits of realignment are:

- A lower stricture rate than with suprapubic catheter placement alone, where stricture formation is almost certain. In some patients, realignment might therefore avoid a prolonged period of suprapubic catheter drainage and a second operation for urethral reconstruction (37,42,43).
- If scarring and subsequent stricture formation occurs, the restoration of urethral continuity is simplified. For short (< 2 cm), non-obliterative strictures, internal urethrotomy can be attempted, with a 50-90% success rate (37,42,44). If not, or in the case of failure of an internal urethrotomy, urethroplasty is required (42).
- If urethroplasty is required later, it is technically easier when the prostate and urethra are well aligned (45).

Endoscopic realignment is the preferred technique (2,30). Using a flexible/rigid cystoscope and biplanar fluoroscopy, a guidewire is placed inside the bladder. Over this, a catheter is placed into the bladder. If necessary, two cystoscopes can be used: one retrograde per urethra and one suprapubic through the bladder neck (37,42,43).

It is important to avoid traction on the Foley balloon catheter since it can damage the remaining sphincter mechanism at the bladder neck. Concomitant bladder neck or rectal injuries or bony fragments inside the bladder must be repaired immediately.

The reasons for immediate repair of bladder neck and rectal injury are:

- Unrepaired bladder neck injury risks incontinence and infection of the pelvic fractures;
- Unrepaired rectal injury carries the obvious risk of sepsis and fistula. Early exploration is indicated to evacuate contaminated haematomas and to perform colostomy if necessary.

Immediate endoscopic realignment can also be performed when the patient is on the operation table for other surgery. Early endoscopic realignment (immediate or delayed primary, see below) is also possible in a stable patient without significant concomitant injuries (42,43).

With modern endoscopic realignment procedures, acceptable rates have been reported for stricture (14-79%), incontinence (\leq 5%) and impotence (10-55%) (42,43). Differences in the rates of incontinence, impotence and re-stricture between series can be explained by differences in patient selection (severe vs less-severe trauma), a mix of partial and complete ruptures, and differences in follow-up duration. Furthermore, these differences make a comparison difficult with other techniques, especially deferred urethroplasty (19,37,42,43). The duration of catheter stay usually varies between 4 and 8 weeks among series (19,37,42,43).

5.6.1.1.1.2.2 Immediate urethroplasty

Immediate urethroplasty with suturing of the urethral ends is difficult because of poor visualization and the inability to assess accurately the degree of urethral disruption, characterized by extensive swelling and ecchymosis. This might lead to extensive urethral debridement (2). Difficulties in identifying structures and planes make it harder to achieve adequate mobilization and subsequent surgical apposition. Another problem is the risk of decompression following entry of the pelvic haematoma, which may result in uncontrolled re-bleeding (2). An extensive review reported a disturbingly high rate of impotence (56%), together with incontinence (21%) and stricture (69%) (41). It is therefore not possible to recommend immediate urethroplasty.

5.6.1.1.2 Delayed primary treatment

Delayed treatment options include delayed primary realignment and delayed primary urethroplasty.

5.6.1.1.2.1 Delayed primary realignment

In the absence of indications for immediate exploration, posterior urethral disruption can be managed in a delayed primary fashion. Primary realignment requires the placement of a suprapubic tube at the time of initial injury, with realignment performed within 14 days (i.e. before fibrosis begins). At that time, patients are stable and most pelvic bleeding has resolved (41,43). The aim and proposed benefits of delayed primary realignment are the same as mentioned for immediate realignment. As for immediate realignment, endoscopic realignment is also the preferred modality for a delayed primary fashion. As most series (34,42) are a mixture of immediate

and delayed primary realignment, see Section 5.6.1.1.1.2.1 Immediate realignment for the results.

Current evidence suggests that early realignment has several potential benefits, particularly in a large distraction defect. It should be performed in an experienced trauma centre.

5.6.1.1.2.2 Delayed primary urethroplasty

Delayed primary urethroplasty is performed no later than 14 days after the initial injury i.e. before the start of the fibrotic process (46,47). If successful, it avoids a long period of suprapubic diversion (46). It is restricted to stable patients with a short distraction defect, who are able to lie down in the lithotomy position (46). Only a few reports have been published in the literature, with good results regarding stricture recurrence, continence and potency rate (46,48,49). However, considering the limited experience available, this approach cannot be generally recommended.

Supporters of early versus delayed intervention state that it does not affect the outcome of an eventual subsequent urethroplasty (50,51). However, some authors have reported worse outcomes of subsequent urethroplasty after failed initial urethral manipulation (realignment or urethroplasty) (46,52,53). Due to this concern and the excellent results obtained with deferred urethroplasty, early realignment or urethroplasty should only be done in experienced centres (50,53).

5.6.1.1.3 Deferred treatment

In the case of a complete rupture, treated with an initial period of 3 months' suprapubic diversion, obliteration of the posterior urethra is almost inevitable (14,41). Treatment options for these posterior urethral strictures are deferred urethroplasty and deferred endoscopic optical incision.

5.6.1.1.3.1 Deferred urethroplasty

Deferred urethroplasty is the procedure of choice for the treatment of posterior urethral distraction defects (30). After 3 months of suprapubic diversion, the pelvic haematoma will have resolved, the prostate will have descended into a more normal position and the scar tissue will have stabilized (46). This technique also has the advantages that associated injuries have resolved by the time it is performed and the patient is clinically stable and able to lie down in the lithotomy position (1,2).

Most posterior urethral distraction defects are short and can be treated using a perineal anastomotic repair (1,46). The key objective is to achieve a tension-free anastomosis between two healthy urethral ends (i.e. after complete excision of any scar tissue) (30,46).

After resection of fibrosis and spatulation of both healthy urethral ends, the gap between both ends is bridged by the so-called 'elaborated perineal approach', which is a series of consecutive manoeuvres, first described by Webster and Ramon (54). The approach has four possible technical stages, with surgery stopped at the stage that first provides a tension-free anastomosis. For large distraction defects and/or complicated cases (bladder neck injuries, fistula, redo-urethroplasty), a combined abdominoperineal approach may be necessary. Results using this approach are good with 80-98% success rates (55-57).

Most urethral stenoses are short and relatively simple and can be treated by mobilization of the bulbar urethra, with or without separation of the corpora cavernosa (46). This is in contrast to the situation in developing countries, where stenoses are more complex, and where additional manoeuvres, such as inferior pubectomy and supracrural rerouting or a combined abdominoperineal approach are needed more often (44,56).

A number of situations may prevent the use of perineal anastomotic repair as either initial or salvage therapy. These situations probably represent < 5% of cases (Table 5.3) (58,59).

Table 5.3: Circumstances that might preclude successful perineal anastomotic repair as either initial or salvage therapy (58,59)

| Circumstance | Alternative procedure |
|---|--|
| Distraction defects longer than 7-8 cm | A tubed interposition flap of penile or perineal skin can be used for reconstruction (60). This is seldom required and most patients that require flap urethroplasties have previous failed repairs of posterior urethral rupture (30). |
| Fistulae | These might require a combined abdominoperineal approach to secure adequate closure (56). |
| Synchronous anterior urethral stricture | The presence of anterior urethral stricture may compromise the blood supply to the bulbar urethra following division of the bulbar arteries. These patients should be treated cautiously. |
| Urinary incontinence | The distal urethral sphincter mechanism can be defunctionalized by urethral distraction, so that urinary continence is maintained primarily by the proximal bladder neck sphincter. Concomitant bladder neck injury might increase incontinence and should require an abdominoperineal procedure to allow simultaneous bladder neck and urethral reconstruction (1,30,56). |

Outcome after deferred urethroplasty is excellent with a stricture rate reported to be around 10% (54,61). Deferred urethroplasty is unlikely to result in additional ED (46,61). It appears that ED is caused by the trauma itself and not by the urethroplasty. Decompression of the erectile nerves after excision of the scar tissue might explain the amelioration of erectile function after urethroplasty (62). Incontinence is rare with deferred urethroplasty (< 4%) (46) and is usually due to incompetence of the bladder neck (30,56).

Standard therapy is a deferred urethroplasty at a minimum of 3 months after trauma, using a one-stage perineal approach whenever possible.

5.6.1.1.3.2 Deferred endoscopic treatment

Cold knife or laser core-through or cut-to-the light urethrotomy for complete urethral obliteration has been described. The results of this technique are disappointing with many patients requiring further urethral manipulations (63,64). This procedure is not recommended.

For short, non-obliterative strictures following realignment or urethroplasty, direct vision urethrotomy can be performed (57). In other cases, urethroplasty is warranted. Repeated urethrotomies and/or dilations must be discouraged because the treatment is only palliative (65).

Stents are not recommended for patients with strictures following pelvic trauma, as fibrotic tissue tends to grow through into the lumen of the stent (1).

5.6.1.2 Penetrating posterior urethral injuries

The management of penetrating posterior urethral injuries is mainly dependent on associated injuries and the clinical condition of the patient (22,23). If possible, immediate exploration by retropubic route and primary repair or realignment can be performed (22,23,30). In the case of rectal injury, a diverting colostomy is necessary (22,23). Life-threatening associated injuries often preclude direct urethral repair. In these cases, suprapubic diversion with delayed abdominoperineal urethroplasty is advised (10,22,23).

5.6.2 Female urethral injuries

Proximal and mid-urethral disruptions require immediate exploration and primary repair by the retropubic and transvaginal routes, respectively, with primary suturing of the urethral ends. Concomitant vaginal lacerations are repaired transvaginally at the same time (2,5,19,29). Distal urethral injuries can be managed vaginally by primary suturing and closure of the vaginal laceration (2,29). Distal urethral injuries can be left unrepaired and hypospadiac because they do not disrupt the sphincteric mechanism (2,5,19,29). It is advisable to use a flap (e.g. Martius) to prevent urethrovaginal fistulas (66).

5.7 Treatment algorithms

The following algorithms are suggested for the treatment of anterior and posterior urethral injuries in men (Figures 5.1 and 5.2).

Figure 5.1: Management of anterior urethral injuries in men

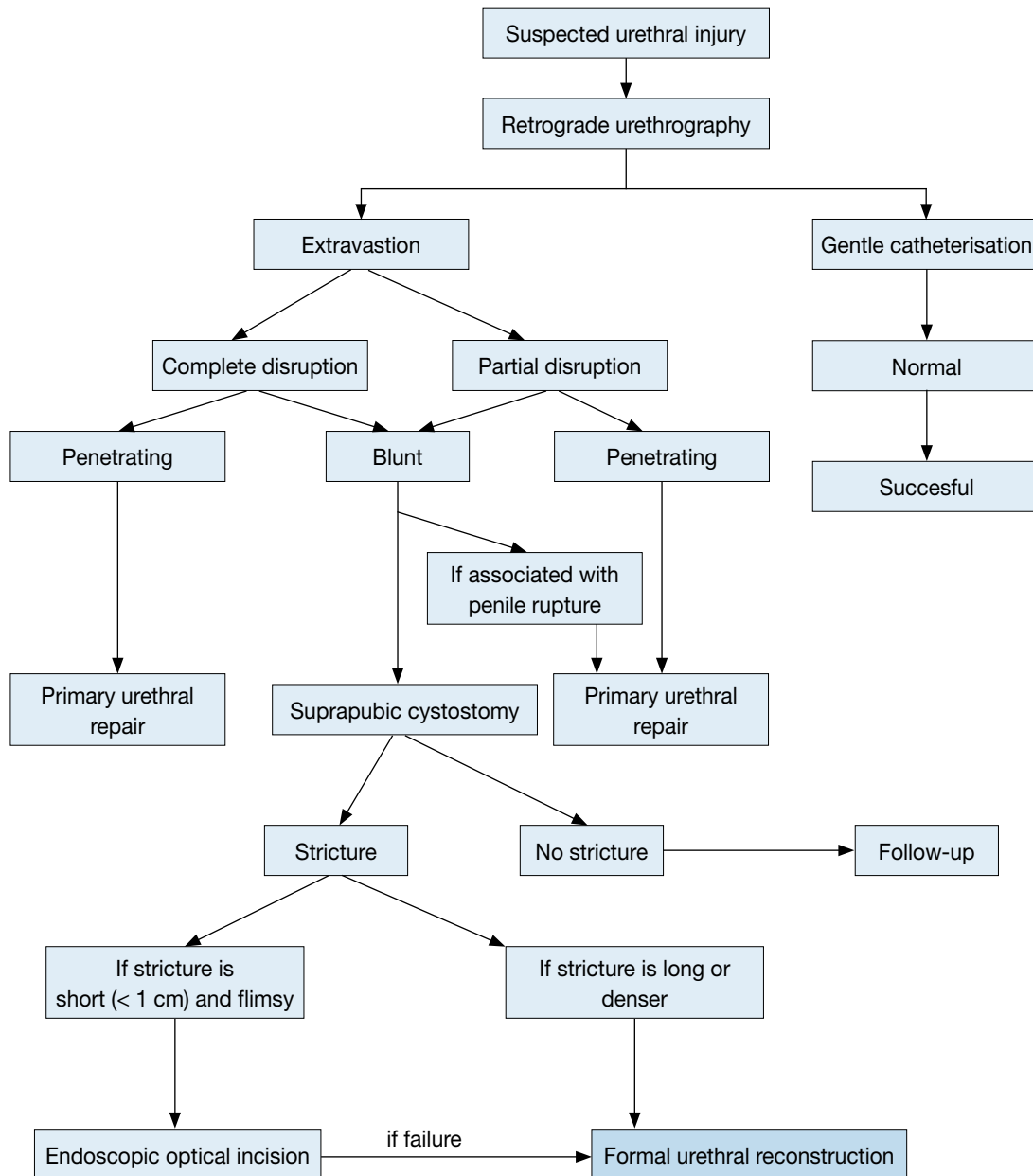
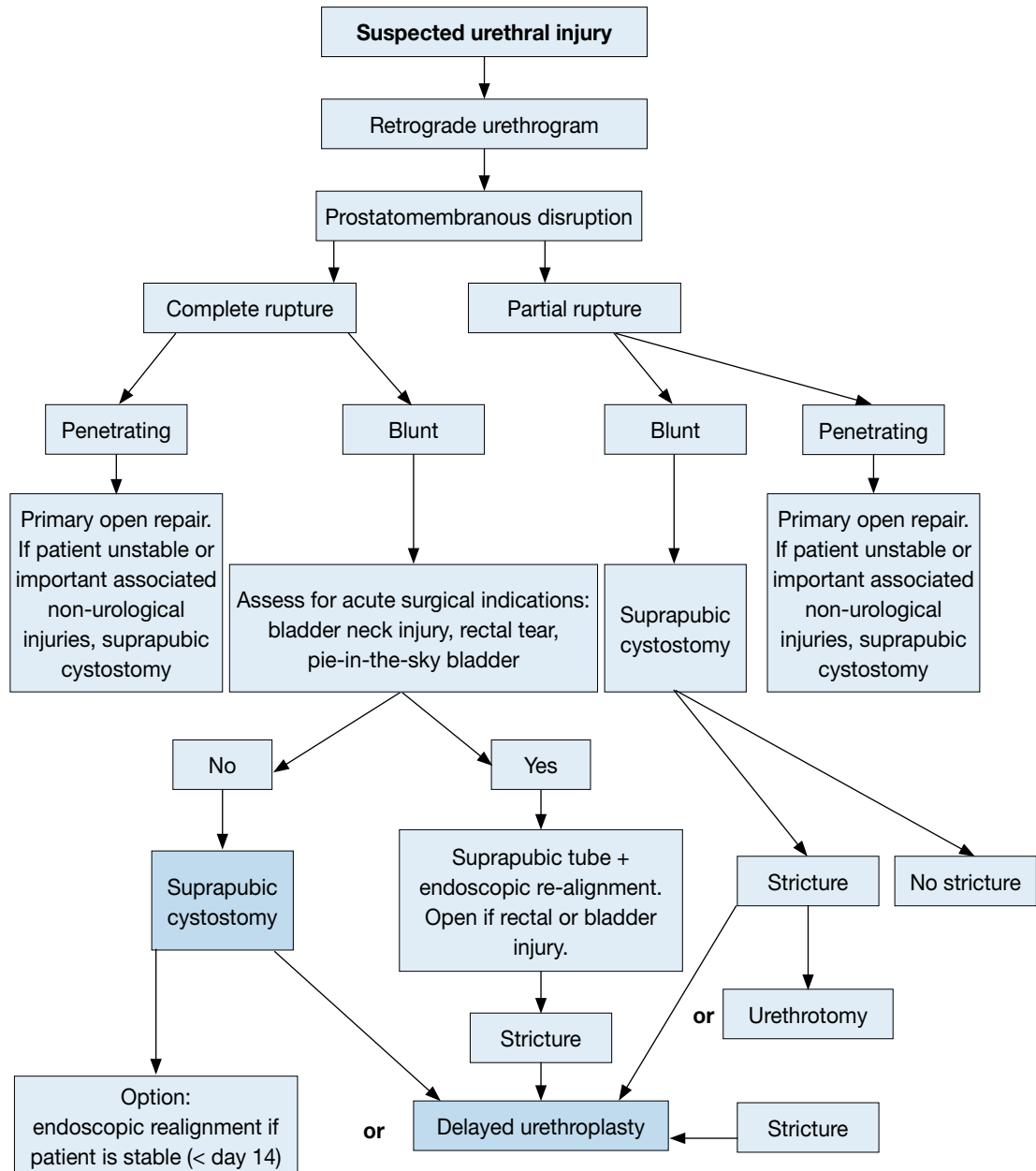


Figure 5.2: Management of posterior urethral injuries in men



5.8 Statements and recommendation on trauma of the urethra

| Statements | LE |
|---|----|
| Blunt trauma accounts for more than 90% of urethral injuries. | 3 |
| In penile fracture the urethra is involved in 20% of cases. | 4 |
| The male posterior urethra is injured in 4-19% of pelvic fracture cases. In industrialized societies pelvic fracture related injuries of the posterior urethra are the most common non iatrogenic injuries. | 3 |
| Erectile dysfunction occurs in 20-60% of patients after traumatic urethral rupture. | 3 |

| Recommendations | GR |
|---|-----------|
| Retrograde urethrography is the gold standard for evaluating urethral injuries. | B |
| Delayed formal urethroplasty is the procedure of choice for the treatment of posterior urethral distraction defects. | B |
| Partial posterior urethral ruptures should be treated by urethral or suprapubic catheterisation. | C |
| In the absence of indications for immediate exploration, posterior urethral injuries may be managed by delayed primary surgery. | C |
| Blunt anterior urethral injuries should be treated by suprapubic diversion. | C |

5.9 Iatrogenic urethral trauma

5.9.1 Introduction

The most common type of urethral trauma seen in modern urological practice is iatrogenic, due to catheterisation, instrumentation, or surgery (14,67). New treatment methods and applied energy sources can also injure the urethra. In most cases, iatrogenic urethral lesions require surgery due to strictures, which vary in their location and degree and require different management strategies (68).

5.9.2 Causes of iatrogenic urethral trauma

5.9.2.1 Transurethral catheterisation

Iatrogenic urethral trauma usually results from improper or prolonged catheterisation and accounts for 32% of strictures. Most of these strictures affect the bulbar urethra (68).

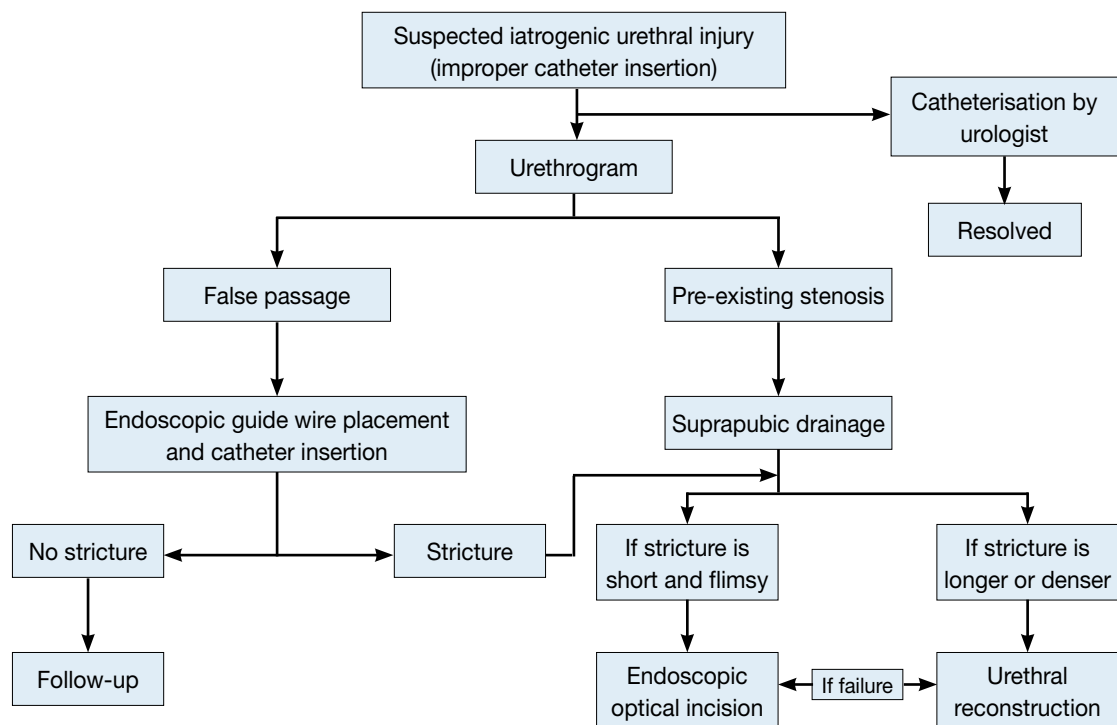
In incorrectly placed transurethral catheters, the pressure needed to fill the balloon and the force associated with manual extraction are much greater than when the catheter is placed correctly. This leads to a greater probability of urethral lesions (69). Improper urethral catheter insertion is a preventable source of urethral trauma in male patients (70). The risk of this type of urethral injury occurring during a hospital stay has been estimated at 3.2 per 1000 cases (68).

Stricture formation due to indwelling catheters is a common problem (67) that primarily affects the anterior urethra. The bladder neck is rarely affected in such cases (71).

It is possible to prevent or reduce the frequency of a wide range of iatrogenic urethral injuries. Implementing training programmes may significantly decrease the incidence, increasing patient safety and reducing the negative long-term effects (67,72).

Male patients undergoing cardiac surgery, such as bypass and other major operations associated with a need for catheterisation, are at risk for urethral trauma and stricture formation. Women undergoing abdominal surgery are also at risk during catheterisation. The size and type of catheter used have an important impact on urethral stricture formation. Current data indicate that silicone catheters and small-calibre Foley catheters are associated with less urethral morbidity (73).

Figure 5.3: Flow diagram of treatment for iatrogenic urethral injury caused by improper insertion of a catheter



5.9.2.2 Transurethral surgery

Transurethral procedures are a common cause of iatrogenic urethral trauma (IUHT). Factors that may influence the development of iatrogenic endoscopic urethral strictures include electrical dispersion generated by unipolar current and the diameter of the instruments used (74).

Predisposing factors most strongly associated with stricture formation in patients undergoing TURP are increasing prostate volume, prostate cancer and the surgeon's experience (75).

Meatal strictures occur as a result of a mismatch between the size of the instrument and the diameter of the urethral meatus. Bulbar strictures occur due to insufficient insulation by the lubricant, causing the monopolar current to leak. To prevent strictures, lubricant gel should be applied carefully in the urethra. The lubricant must be reapplied when the resection time is prolonged (76). Internal urethrotomy must be performed before TURP if there are pre-existing meatal or urethral strictures (76).

There appears to be no relationship with the duration of procedures or the method used (holmium laser or traditional TURP) on the rate of stricture formation (77).

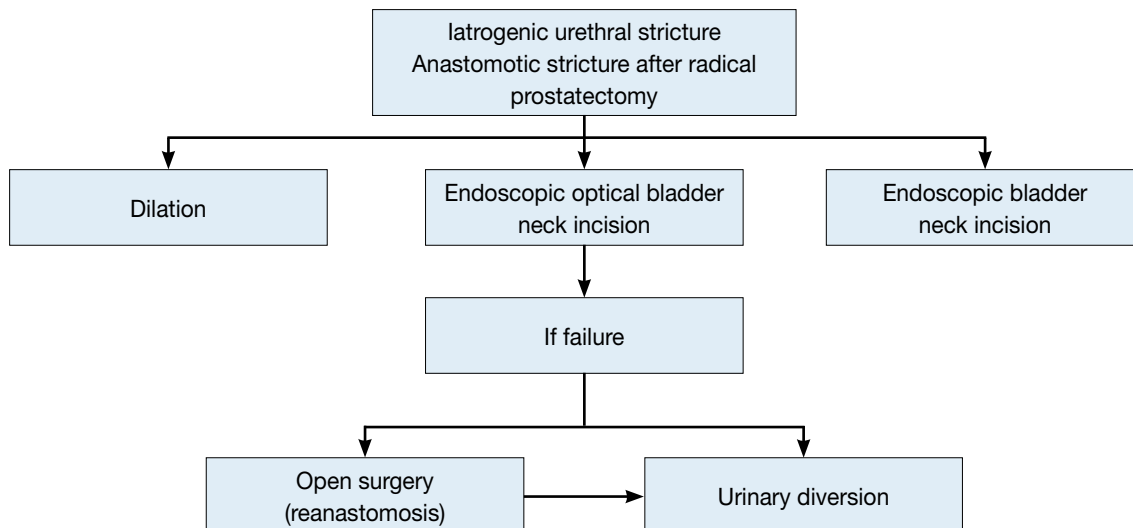
5.9.2.3 Surgical treatment for prostate cancer

Urethral stricture following prostate cancer treatment can occur anywhere from the bladder neck to the urethral meatus. The rate of bladder neck constriction after radical prostatectomy varies with the definition of the stricture used and individual practice (78,79). The Cancer of the Prostate Strategic Urologic Research Endeavour (CaPSURE) database shows an incidence of urethral stricture after various forms of prostate cancer therapy of 1.1-8.4%. The risk is greatest after radical prostatectomy if combined with external-beam radiation therapy. In a multivariate analysis, primary treatment type, age, and obesity were found to be significant predictors for stricture development (78).

Robot-assisted prostatectomy also affects urinary function and the risk of iatrogenic trauma. Iatrogenic complications involving the bladder neck account for 2.2%, similar to the stricture rate found with conventional treatment for localised prostate cancer (80).

Anastomotic stricture is also a complication in conventional laparoscopic prostatectomy. If prospective studies only are taken into account, there is no significant difference in the anastomotic stricture rate between laparoscopic and robot-assisted radical prostatectomy (81).

Figure 5.4: Flow diagram of treatment for stricture after radical prostatectomy



5.9.2.4 Radiotherapy for prostate cancer

The development of urinary fistulae has been reported after brachytherapy and radical prostatectomy, with incidences of 0.3-3.0% and 0-0.6%, respectively. Most fistulae involve the rectum (82,83). Brachytherapy is a recognised cause of strictures in patients with localised prostate cancer, as the CaPSURE study has shown (84). Previous TURP increases the risk of stricture formation (85,86).

5.9.2.5 Major abdominal surgery and cystectomy

Iatrogenic injuries to the urethra can be a complication of abdominal and pelvic procedures. Bladder and urethral catheterisation must therefore be carried out preoperatively to prevent these complications (87). Radical cystectomy and subsequent urinary diversion may also cause urethral trauma (88). Table 5.4 lists the most common causes of urethral trauma.

Table 5.4: Most common causes of urethral trauma

| Procedure | Percentage |
|---|---|
| Catheterisation | 32% of iatrogenic urethral strictures (52% bulbar urethra) |
| Urethral instrumentation for therapy and/or diagnosis | |
| Treatment for prostatic disease | 1.1-8.4% urethral stricture rate |
| Transurethral surgery (e.g. TURB/TURP) | 2.2-9.8% urethral stricture rate |
| Radical prostatectomy | 0.5-32% bladder neck constriction; no difference between LRP and RALP (relative risk: 1.42; 95% confidence interval for relative risk, 0.40-5.06; p = 0.59) |
| Radiotherapy (percutaneous or brachytherapy) | 6% urethral stricture rate, 0.3-3.0% urinary fistula rate |
| Greatest risk for urethral stricture is found for the combination of radical prostatectomy and EBRT | |
| Cryotherapy | |
| HIFU | |
| Treatment for bladder disease | |
| TURB | |
| Cystectomy | 3.1% subneovesical obstruction, 1.2% neovesicourethral anastomotic strictures, 0.9% urethral strictures |
| Injury during major abdominal and pelvic operations | |

TURB = transurethral resection of the bladder; TURP = transurethral resection of the prostate; LRP = laparoscopic radical prostatectomy; RALP = robot-assisted laparoscopic radical prostatectomy; EBRT = external-beam radiation therapy; HIFU = high-intensity focused ultrasound.

5.9.3 Symptoms of iatrogenic urethral injury

Symptoms of urethral lesions caused by improper catheterisation or instrumentation are penile and/or perineal pain (100%) and urethral bleeding (86%) (71). Failure to diagnose accurately and treat urethral injuries may lead to significant long-term sequelae, in most cases presenting as strictures (89,90).

5.9.4 Diagnosis

Uroflowmetry, urethrography, and/or urethroscopy are the key investigations in diagnosis, and the algorithm is the same for acute and delayed symptoms. In the acute phase, the symptoms are bleeding and difficulty during catheterisation. Delayed symptoms include worsening of flow and other symptoms of obstruction.

5.9.5 Treatment

The value of temporary stenting in minor urethral injuries is unproven. Temporary stenting with an indwelling catheter is the conventional treatment option for an acute false passage (91). In difficult cases, it may be assisted by cystoscopy and guidewire placement (92). Suprapubic catheterisation is an alternative.

Endoscopic management, either with incision or resection, can successfully treat iatrogenic prostatic urethral strictures. Indwelling catheter placement or an open procedure, associated with increased morbidity, are alternatives (93).

Urethral lesions following radiotherapy are often more difficult to treat and may require complex reconstructive surgery (82,83). Section 5.10 lists the statements and recommendations regarding the iatrogenic causes of urethral trauma.

5.10 Statements and recommendations regarding iatrogenic urethral trauma

| Statements | LE |
|--|----|
| Iatrogenic causes are the most common type of urethral injury in Europe and therefore the most common cause of urethral stricture formation. | 2a |
| Implementing training programmes on urinary catheter insertion significantly improves the rate of catheter-related complications. | 2b |
| New technologies represent an additional source of urethral injury. | 3 |

| Recommendations | GR |
|--|----|
| Proper training should be provided to reduce the risk of traumatic catheterisation. | A |
| Urethral instrumentation should only be carried out when there are valid clinical indications. | A |
| When catheterisation is necessary, its duration should be kept to a minimum. | B |

LE= level of evidence; GR = grade of recommendation.

5.11 References

- Chapple C, Barbagli G, Jordan G, et al. Consensus statement on urethral trauma. *BJU Int* 2004 Jun;93(9):1195-202.
<http://www.ncbi.nlm.nih.gov/pubmed/15180604>
- Brandes S. Initial management of anterior and posterior urethral injuries. *Urol Clin North Am* 2006 Feb;33(1):87-95,vii.
<http://www.ncbi.nlm.nih.gov/pubmed/16488283>
- Park S, McAninch JW. Straddle injuries to the bulbar urethra: management and outcomes in 78 patients. *J Urol* 2004 Feb;171(2 Pt 1):722-5.
<http://www.ncbi.nlm.nih.gov/pubmed/14713796>
- Elgammal MA. Straddle injuries to the bulbar urethra: management and outcome in 53 patients. *Int Braz J Urol* 2009 Jul-Aug;35(4):450-8.
<http://www.ncbi.nlm.nih.gov/pubmed/19719861>
- Kommu SS, Illahi I, Mumtaz F. Patterns of urethral injury and immediate management. *Curr Opin Urol* 2007 Nov;17(6):383-9.
<http://www.ncbi.nlm.nih.gov/pubmed/17921771>
- Rosenstein DI, Alsikafi NF. Diagnosis and classification of urethral injuries. *Urol Clin North Am* 2006 Feb;33(1):73-85,vi-vii.
<http://www.ncbi.nlm.nih.gov/pubmed/16488282>
- Phonsombat S, Master VA, McAninch JW. Penetrating external genital trauma: a 30-year single institution experience. *J Urol* 2008 Jul;180(1):192-5;discussion 195-6.
<http://www.ncbi.nlm.nih.gov/pubmed/18499189>
- Simhan J, Rothman J, Canter D, et al. Gunshot wounds to the scrotum: a large single-institutional 20-year experience. *BJU Int* 2012 Jun;109(11):1704-7.
<http://www.ncbi.nlm.nih.gov/pubmed/21992688>
- Kunkle DA, Lebed BD, Mydlo JH, et al. Evaluation and management of gunshot wounds of the penis: 20-year experience at an urban trauma center. *J Trauma* 2008 Apr;64(4):1038-42.
<http://www.ncbi.nlm.nih.gov/pubmed/18404072>
- Bjurlin MA, Kim DY, Zhao LC, et al. Clinical characteristics and surgical outcomes of penetrating external genital injuries. *J Trauma Acute Care Surg* 2013 Mar;74(3):839-44.
<http://www.ncbi.nlm.nih.gov/pubmed/23425745>
- Amit A, Arun K, Bharat B, et al. Penile fracture and associated urethral injury: Experience at a tertiary care hospital. *Can Urol Assoc J* 2013 Mar-Apr;7(3-4):E168-70.
<http://www.ncbi.nlm.nih.gov/pubmed/23589751>
- Lumen N, Hoebeke P, Willemsen P, et al. Etiology of urethral stricture disease in the 21st century. *J Urol* 2009 Sep;182(3):983-7.
<http://www.ncbi.nlm.nih.gov/pubmed/19616805>
- Palminteri E, Berdondini E, Verze P, et al. Contemporary urethral stricture characteristics in the developed world. *Urology* 2013 Jan;81(1):191-6.
<http://www.ncbi.nlm.nih.gov/pubmed/23153951>
- Mundy A, Andrich D. Urethral trauma. Part I: introduction, history, anatomy, pathology, assessment and emergency management. *BJUI* 2011 Aug;108(3):310-27.
<http://www.ncbi.nlm.nih.gov/pubmed/21771241>
- Bjurlin MA, Fantus RJ, Mellett MM, et al. Genitourinary injuries in pelvic fracture morbidity and mortality using the National Trauma Data Bank. *J Trauma* 2009 Nov;67(5):1033-9.
<http://www.ncbi.nlm.nih.gov/pubmed/19901665>
- Basta AM, Blackmore CC and Wessells H. Predicting urethral injury from pelvic fracture patterns in male patients with blunt trauma. *J Urol* 2007 Feb;177(2):571-5.
<http://www.ncbi.nlm.nih.gov/pubmed/17222635>
- Andrich DE, Day AC, Mundy AR. Proposed mechanisms of lower urinary tract injury in fractures of the pelvic ring. *BJU Int* 2007 Sep;100(3):567-73.
<http://www.ncbi.nlm.nih.gov/pubmed/17608826>

18. Mouraviev VB, Santucci RA. Cadaveric anatomy of pelvic fracture urethral distraction injury: most injuries are distal to the external urinary sphincter. *J Urol* 2005;173(3):869-72.
<http://www.ncbi.nlm.nih.gov/pubmed/15711301>
19. Figler B, Hoffer CE, Reisman W, et al. Multi-disciplinary update on pelvic fracture associated bladder and urethral injuries. *Injury* 2012 Aug;43(8):1242-9.
<http://www.ncbi.nlm.nih.gov/pubmed/22592152>
20. Koraitim MM, Marzouk ME, Atta MA, et al. Risk factors and mechanism of urethral injury in pelvic fractures. *Br J Urol* 1996 Jun;77(6):876-80.
<http://www.ncbi.nlm.nih.gov/pubmed/8705225>
21. Mundy A, Andrich D. Pelvic fracture-related injuries of the bladder neck and prostate: their nature, cause and management. *BJU Int* 2010 May;105(9):1302-8.
<http://www.ncbi.nlm.nih.gov/pubmed/19874306>
22. Tausch TJ, Cavalcanti AG, Soderdahl DW, et al. Gunshot wound injuries of the prostate and posterior urethra: reconstructive armamentarium. *J Urol* 2007 Oct;178(4 Pt 1):1346-8.
<http://www.ncbi.nlm.nih.gov/pubmed/17706720>
23. Cinman NM, McAninch JW, Porten SP, et al. Gunshot wounds to the lower urinary tract: a single-institution experience. *J Trauma Acute Care Surg* 2013 Mar;74(3):725-30;discussion 730-1.
<http://www.ncbi.nlm.nih.gov/pubmed/23425728>
24. Koraitim MM. Predictors of erectile dysfunction post pelvic fracture urethral injuries: a multivariate analysis. *Urology* 2013 May;81(5):1081-5.
<http://www.ncbi.nlm.nih.gov/pubmed/23465164>
25. Feng C, Xu YM, Yu JJ, et al. Risk factors for erectile dysfunction in patients with urethral strictures secondary to blunt trauma. *J Sex Med* 2008 Nov;5(11):2656-61.
<http://www.ncbi.nlm.nih.gov/pubmed/18564154>
26. Metzke M, Tiemann AH, Josten C. Male sexual dysfunction after pelvic fracture. *J Trauma* 2007 Aug;63(2):394-401.
<http://www.ncbi.nlm.nih.gov/pubmed/17693842>
27. Koraitim MM, Reda IS. Role of magnetic resonance imaging in assessment of posterior urethral distraction defects. *Urology* 2007 Sep;70:403-6.
<http://www.ncbi.nlm.nih.gov/pubmed/17905082>
28. Sorensen MD, Wessells H, Rivara FP, et al. Prevalence and predictors of sexual dysfunction 12 months after major trauma: a national study. *J Trauma* 2008;65(5):1045-52;discussion 1052-3.
<http://www.ncbi.nlm.nih.gov/pubmed/19001972>
29. Koraitim MM. Pelvic fracture urethral injuries: the unresolved controversy. *J Urol* 1999 May;161(5):1433-41.
<http://www.ncbi.nlm.nih.gov/pubmed/10210368>
30. Mundy AR, Andrich DE. Urethral trauma. Part II: Types of injury and their management. *BJU Int* 2011 Sep;108(5):630-50. [No abstract available]
<http://www.ncbi.nlm.nih.gov/pubmed/21854524>
31. Spencer Netto FA, Hamilton P, Kodama R, et al. Retrograde urethrocytography impairs computed tomography diagnosis of pelvic arterial hemorrhage in the presence of a lower urologic tract injury. *J Am Coll Surg* 2008 Feb;206(2):322-7.
<http://www.ncbi.nlm.nih.gov/pubmed/18222387>
32. Chou CP, Huang JS, Wu MT, et al. CT voiding urethrography and virtual urethroscopy: preliminary study with 16-MDCT. *AJR Am J Roentgenol* 2005 Jun;184(6):1882-8.
<http://www.ncbi.nlm.nih.gov/pubmed/15908546>
33. Zhang XM, Hu WL, He Hx, et al. Diagnosis of male posterior urethral stricture: comparison of 64-MDCT urethrography vs. standard urethrography. *Abdom Imaging* 2011 Dec;36(6):771-5.
<http://www.ncbi.nlm.nih.gov/pubmed/21165616>
34. Kielb SJ, Voeltz ZL and Wolf JS. Evaluation and management of traumatic posterior urethral disruption with flexible cystourethroscopy. *J Trauma* 2001 Jan;50(1):36-40.
<http://www.ncbi.nlm.nih.gov/pubmed/11253761>
35. Mazaris EM, Livadas K, Chalikopoulos D, et al. Penile fractures: immediate surgical approach with a midline ventral incision. *BJU Int* 2009 Aug;104(4):520-3.
<http://www.ncbi.nlm.nih.gov/pubmed/19239439>
36. Kamdar C, Mooppan UM, Kim H, et al. Penile fracture: preoperative evaluation and surgical technique for optimal patient outcome. *BJU Int* 2008;102(11):1640-4;discussion 1644.
<http://www.ncbi.nlm.nih.gov/pubmed/18710448>

37. Mouraviev VB, Coburn M, Santucci RA. The treatment of posterior urethral disruption associated with pelvic fractures: comparative experience of early realignment versus delayed urethroplasty. *J Urol* 2005 Mar;173(3):873-6.
<http://www.ncbi.nlm.nih.gov/pubmed/15711301>
38. Derouiche A, Belhaj K, Hentati H, et al. Management of penile fractures complicated by urethral rupture. *Int J Impot Res* 2008 Jan-Feb;20(1):111-4.
<http://www.ncbi.nlm.nih.gov/pubmed/17673928>
39. Jack GS, Garraway I, Reznicek R, et al. Current treatment options for penile fractures. *Rev Urol* 2004 Summer;6(3):114-20.
<http://www.ncbi.nlm.nih.gov/pubmed/16985591>
40. Cavalcanti AG, Krambeck R, Araújo A, et al. Management of urethral lesions in penile blunt trauma. *Int J Urol* 2006 Sep;13(9):1218-20.
<http://www.ncbi.nlm.nih.gov/pubmed/16984556>
41. Koraitim MM. Pelvic fracture urethral injuries: evaluation of various methods of management. *J Urol* 1996 Oct;156(4):1288-91.
<http://www.ncbi.nlm.nih.gov/pubmed/8808856>
42. Leddy LS, Vanni AJ, Wessells H, et al. Outcomes of endoscopic realignment of pelvic fracture associated urethral injuries at a level 1 trauma center. *J Urol* 2012 Jul;188(1):174-8.
<http://www.ncbi.nlm.nih.gov/pubmed/22591965>
43. Moudouni SM, Patard JJ, Manunta A, et al. Early endoscopic realignment of post-traumatic posterior urethral disruption. *Urology* 2001 Apr;57(4):628-32.
<http://www.ncbi.nlm.nih.gov/pubmed/11306365>
44. Kulkarni SB, Barbagli G, Kulkani JS, et al. Posterior urethral stricture after pelvic fracture urethral distraction defects in developing and developed countries, and choice of surgical technique. *J Urol* 2010 Mar;183(3):1049-54.
<http://www.ncbi.nlm.nih.gov/pubmed/20092843>
45. Koraitim MM. Unsuccessful outcomes after posterior urethroplasty: definition, diagnosis, and treatment. *Urology* 2012 May;79(5):1168-73.
<http://www.ncbi.nlm.nih.gov/pubmed/22449452>
46. Lumen N, Hoebeke P, Troyer BD, et al. Perineal anastomotic urethroplasty for posttraumatic urethral stricture with or without previous urethral manipulations: a review of 61 cases with long-term followup. *J Urol* 2009 Mar;181(3):1196-200.
<http://www.ncbi.nlm.nih.gov/pubmed/19152939>
47. Mundy AR. The role of delayed primary repair in the acute management of pelvic fracture injuries of the urethra. *Br J Urol* 1991 Sep;68(3):273-6.
<http://www.ncbi.nlm.nih.gov/pubmed/1913069>
48. Aboutaieb R, Sarf I, Dakir M, et al. [Surgical treatment of traumatic ruptures of the posterior urethra.] *Prog Urol* 2000 Feb;10(1):58-64. [Article in French]
<http://www.ncbi.nlm.nih.gov/pubmed/10785920>
49. Sfaxi M, El Atat R, Ben Hassine L, et al. [Surgical treatment of post-traumatic complete urethral rupture: deferred urgent urethral suture or delayed repair?] *Prog Urol* 2006 Sep;16(4):464-9. [Article in French]
<http://www.ncbi.nlm.nih.gov/pubmed/17069041>
50. Sofer M, Mabjeesh NJ, Ben-Chaim J, et al. Long-term results of early endoscopic realignment of complete posterior urethral disruption. *J Endourol* 2010 Jul;24(7):1117-21.
<http://www.ncbi.nlm.nih.gov/pubmed/20590470>
51. Elliott DS, Barrett DM. Long-term followup and evaluation of primary realignment of posterior urethral disruptions. *J Urol* 1997 Mar;157(3):814-6.
<http://www.ncbi.nlm.nih.gov/pubmed/9072573>
52. Culty T, Boccon-Gibod L. Anastomotic urethroplasty for posttraumatic urethral stricture: previous urethral manipulation has a negative impact on the final outcome. *J Urol* 2007 Apr;177(4):1374-7.
<http://www.ncbi.nlm.nih.gov/pubmed/17382735>
53. Singh BP, Andankar MG, Swain SK, et al. Impact of prior urethral manipulation on outcome of anastomotic urethroplasty for post-traumatic urethral stricture. *Urology* 2010 Jan;75(1):179-82.
<http://www.ncbi.nlm.nih.gov/pubmed/19854488>
54. Webster GD, Ramon J. Repair of pelvic fracture posterior urethral defects using an elaborated perineal approach: experience with 74 cases. *J Urol* 1991 Apr;145(4):744-8.
<http://www.ncbi.nlm.nih.gov/pubmed/2005693>

55. Kizer WS, Armenakas NA, Brandes SB, et al. Simplified reconstruction of posterior urethral disruption defects: limited role of supracrural rerouting. *J Urol* 2007 Apr;177(4):1378-81;discussion 1381-2. <http://www.ncbi.nlm.nih.gov/pubmed/17382736>
56. Koraitim MM. On the art of anastomotic posterior urethroplasty: a 27-year experience. *J Urol* 2005 Jan;173(1):135-9. <http://www.ncbi.nlm.nih.gov/pubmed/15592055>
57. Cooperberg MR, McAninch JW, Alsikafi NF, et al. Urethral reconstruction for traumatic posterior urethral disruption: outcomes of a 25-year experience. *J Urol* 2007 Nov;178(5):2006-10. <http://www.ncbi.nlm.nih.gov/pubmed/17869302>
58. Webster GD, Ramon J, Kreder KJ. Salvage posterior urethroplasty after failed initial repair of pelvic fracture membranous urethral defects. *J Urol* 1990 Dec;144(6):1370-2. <http://www.ncbi.nlm.nih.gov/pubmed/2231930>
59. MacDiarmid S, Rosario D, Chapple CR. The importance of accurate assessment and conservative management of the open bladder neck in patients with post-pelvic fracture membranous urethral distraction defects. *Br J Urol* 1995 Jan;75(1):65-7. <http://www.ncbi.nlm.nih.gov/pubmed/7850300>
60. Oosterlinck W, Lumen N, Van Cauwenberghe G. [Surgical treatment of urethral stenoses: technical aspects.] *Ann Urol (Paris)* 2007 Aug;41(4):173-207. [Article in French] <http://www.ncbi.nlm.nih.gov/pubmed/18260607>
61. Fu Q, Zhang J, Sa YL, et al. Recurrence and complications after transperineal bulboprostatic anastomosis for posterior urethral strictures resulting from pelvic fracture: a retrospective study from a urethral referral centre. *BJU Int* 2013 Aug;112(4):E358-63. <http://www.ncbi.nlm.nih.gov/pubmed/23773274>
62. Feng C, Xu YM, Barbagli G, et al. The relationship between erectile dysfunction and open urethroplasty: a systematic review and meta-analysis. *J Sex Med* 2013 Aug;10(8):2060-8. <http://www.ncbi.nlm.nih.gov/pubmed/23656595>
63. Levine J, Wessells H. Comparison of open and endoscopic treatment of posttraumatic posterior urethral strictures. *World J Surg* 2001 Dec;25(12):1597-601. <http://www.ncbi.nlm.nih.gov/pubmed/11775198>
64. Goel MC, Kumar M, Kapoor R. Endoscopic management of traumatic posterior urethral stricture: early results and followup. *J Urol* 1997 Jan;157(1):95-7. <http://www.ncbi.nlm.nih.gov/pubmed/8976224>
65. Santucci R, Eisenberg L. Urethrotomy has a much lower success rate than previously reported. *J Urol* 2010 May;183(5):1859-62. <http://www.ncbi.nlm.nih.gov/pubmed/20303110>
66. Singh O, Gupta SS, Mathur RK. Urogenital fistulas in women: 5-year experience at a single center. *Urol J* 2010 Winter;7(1):35-9. <http://www.ncbi.nlm.nih.gov/pubmed/20209454>
67. Kashefi C, Messer K, Barden R, et al. Incidence and prevention of iatrogenic urethral injuries: *J Urol* 2008 Jun;179(6):2254-7. <http://www.ncbi.nlm.nih.gov/pubmed/18423712>
68. Fenton AS, Morey AF, Aviles R, et al. Anterior urethral stricture: etiology and characteristics. *Urology* 2005 Jun;65(6):1055-8. <http://www.ncbi.nlm.nih.gov/pubmed/15913734>
69. Wu AK, Blaschko SD, Garcia M, et al. Safer urethral catheters: how study of catheter balloon pressure and force can guide design. *BJU Int* 2012 Apr;109(7):1110-4. <http://www.ncbi.nlm.nih.gov/pubmed/21871052>
70. Buddha S. Complication of urethral catheterisation. *Lancet* 2005 Mar;365(9462):909. <http://www.ncbi.nlm.nih.gov/pubmed/15752537>
71. Hammarsten J, Lindqvist K. Suprapubic catheter following transurethral resection of the prostate: a way to decrease the number of urethral strictures and improve the outcome of operations. *J Urol* 1992 Mar;147(3):648-51. <http://www.ncbi.nlm.nih.gov/pubmed/1538447>
72. Thomas AZ, Giri SK, Meagher D, et al. Avoidable iatrogenic complications of urethral catheterization and inadequate intern training in a tertiary-care teaching hospital. *BJU Int* 2009 Oct;104(8):1109-12. <http://www.ncbi.nlm.nih.gov/pubmed/19338562>
73. Katz G, Milgalter E, Landau Y, et al. Prevention of urethral strictures following coronary artery bypass graft surgery. *Urology* 1992 May;39(5):433-5. <http://www.ncbi.nlm.nih.gov/pubmed/1580032>

74. Vicente J, Rosales A, Montlleó M, et al. Value of electrical dispersion as a cause of urethral stenosis after endoscopic surgery. *Eur Urol* 1992;21(4):280-3.
<http://www.ncbi.nlm.nih.gov/pubmed/1459149>
75. Hammarsten J, Lindqvist K, Sunzel H. Urethral strictures following transurethral resection of the prostate. The role of the catheter. *Br J Urol* 1989 Apr;63(4):397-400.
<http://www.ncbi.nlm.nih.gov/pubmed/2713622>
76. Rassweiler J, Teber D, Kuntz R, et al. Complications of transurethral resection of the prostate (TURP)--incidence, management, and prevention. *Eur Urol* 2006 Nov;50(5):969-79;discussion 980.
<http://www.ncbi.nlm.nih.gov/pubmed/16469429>
77. Eltabey MA, Sherif H, Hussein AA. Holmium laser enucleation versus transurethral resection of the prostate. *Can J Urol* 2010 Dec;17(6):5447-52.
<http://www.ncbi.nlm.nih.gov/pubmed/21172109>
78. Elliott SP, Meng MV, Elkin EP, et al; CaPSURE investigators. Incidence of urethral stricture after primary treatment for prostate cancer: data from CaPSURE. *J Urol* 2007 Aug;178(2):529-34.
<http://www.ncbi.nlm.nih.gov/pubmed/17570425>
79. Park R, Martin S, Goldberg JD, et al. Anastomotic strictures following radical prostatectomy: insights into incidence, effectiveness of intervention, effect on continence, and factors predisposing to occurrence. *Urology* 2001 Apr;57(4):742-6.
<http://www.ncbi.nlm.nih.gov/pubmed/11306394>
80. Msezane LP, Reynolds WS, Gofrit ON, et al. Bladder neck contracture after robot-assisted laparoscopic radical prostatectomy: evaluation of incidence and risk factors and impact on urinary function. *J Endourol* 2008 Jan;22(1):97-104.
<http://www.ncbi.nlm.nih.gov/pubmed/18326071>
81. Ficarra V, Novara G, Artibani W, et al. Retropubic, laparoscopic, and robot-assisted radical prostatectomy: a systematic review and cumulative analysis of comparative studies. *Eur Urol* 2009 May;55(5):1037-63.
<http://www.ncbi.nlm.nih.gov/pubmed/19185977>
82. Chrouser KL, Leibovich BC, Sweat SD, et al. Urinary fistulas following external radiation or permanent brachytherapy for the treatment of prostate cancer. *J Urol* 2005 Jun;173(6):1953-7.
<http://www.ncbi.nlm.nih.gov/pubmed/15879789>
83. Marguet C, Raj GV, Brashears JH, et al. Rectourethral fistula after combination radiotherapy for prostate cancer. *Urology* 2007 May;69(5):898-901.
<http://www.ncbi.nlm.nih.gov/pubmed/17482930>
84. Gómez-Iturriaga Piña A, Crook J, Borg J, et al. Median 5 year follow-up of 125iodine brachytherapy as monotherapy in men aged <or=55 years with favorable prostate cancer. *Urology* 2010 Jun;75(6):1412-6.
<http://www.ncbi.nlm.nih.gov/pubmed/20035986>
85. Fonteyne V, Villeirs G, Lumen N, et al. Urinary toxicity after high dose intensity modulated radiotherapy as primary therapy for prostate cancer. *Radiother Oncol* 2009 Jul;92(1):42-7.
<http://www.ncbi.nlm.nih.gov/pubmed/19356817>
86. Shelley M, Wilt TJ, Coles B, et al. Cryotherapy for localised prostate cancer. *Cochrane Database Syst Rev* 2007 Jul;(3):CD005010.
<http://www.ncbi.nlm.nih.gov/pubmed/17636783>
87. Polat O, Gül O, Aksoy Y, et al. Iatrogenic injuries to ureter, bladder and urethra during abdominal and pelvic operations. *Int Urol Nephrol* 1997;29(1):13-8.
<http://www.ncbi.nlm.nih.gov/pubmed/9203032>
88. Hautmann RE, de Petriconi RC, Volkmer BG. 25 years of experience with 1,000 neobladders: longterm complications. *J Urol* 2011 Jun;185(6):2207-12.
<http://www.ncbi.nlm.nih.gov/pubmed/21497841>
89. Hadjizacharia P, Inaba K, Teixeira PG, et al. Evaluation of immediate endoscopic realignment as a treatment modality for traumatic urethral injuries. *J Trauma* 2008 Jun;64(6):1443-9.
<http://www.ncbi.nlm.nih.gov/pubmed/18545107>
90. Rieder J, Brusky J, Tran V, et al. Review of intentionally self-inflicted, accidental and iatrogenic foreign objects in the genitourinary tract. *Urol Int* 2010;84(4):471-5.
<http://www.ncbi.nlm.nih.gov/pubmed/20224259>
91. Gökalp A, Yildirim I, Aydur E, et al. How to manage acute urethral false passage due to intermittent catheterization in spinal cord injured patients who refused insertion of an indwelling catheter. *J Urol* 2003 Jan;169(1):203-6.
<http://www.ncbi.nlm.nih.gov/pubmed/12478136>

92. Maheshwari PN, Shah HN. Immediate endoscopic management of complete iatrogenic anterior urethral injuries: a case series with long-term results. *BMC Urol* 2005 Nov;5:13. <http://www.ncbi.nlm.nih.gov/pubmed/16281970>
93. Pansadoro V, Emiliozzi P. Iatrogenic prostatic urethral strictures: classification and endoscopic treatment. *Urology* 1999 Apr;53(4):784-9. <http://www.ncbi.nlm.nih.gov/pubmed/10197857>

6. GENITAL TRAUMA

6.1 Introduction and background

Genitourinary trauma is seen in both sexes and in all age groups. Of all urological injuries, 33-66% involve the external genitalia (1). Genital trauma is much more common in males than in females, especially between the ages of 15 and 40 years. This is due to anatomical differences, increased frequency of road traffic accidents and increased participation in physical sports, war and violent crime.

Genital trauma is commonly caused by blunt injuries (80%). The risk of associated injuries to neighbouring organs (bladder, urethra, vagina, rectum and bowel) after blunt trauma is higher in females than in males. In males, blunt genital trauma frequently occurs unilaterally, only approximately 1% present as bilateral scrotal or testicular injuries (2).

Any kind of contact sport, without the use of necessary protective aids, may be associated with genital trauma. Off-road bicycling and motorbike riding (especially on motorbikes with a dominant petrol tank), rugby, football and hockey are all activities which have been associated with blunt testicular trauma (3-6).

Penetrating injuries account for 20% of genitourinary trauma, with 40-60% of all penetrating genitourinary lesions involving the external genitalia (7,8). Thirty-five per cent of all genitourinary gunshot wounds involve the genitalia (2). In a recent series of wartime genitourinary injuries, 71.5% of 361 operations involved the external genitalia - the majority caused by improvised explosive devices (IEDs) and other explosive ordinance. A smaller number were due to gunshot injuries (9). In both males and females, penetrating genital injuries occur with other associated injuries in 70% of patients. In males, penetrating scrotal injuries affect both testes in 30% of cases (2,10) compared with blunt scrotal injuries.

Self-mutilation of the external genitalia has also been reported in psychotic patients and transsexuals (11). Genital burns are rare in isolation, usually due to industrial flame or chemicals in adults, and all but the full-thickness type are treated conservatively (12). Both male and female genital piercings increase the risk for unexpected genital trauma (13). Although there is an increased risk of Hepatitis B and C in genitally injured patients, there is no higher incidence of STDs in patients with genital piercing (13).

6.2 General principles and pathophysiology

In genital trauma, a urinalysis should be performed. The presence of macro- and or micro-haematuria requires a retrograde urethrogram in males. In females, flexible or rigid cystoscopy has been recommended to exclude urethral and bladder injury (14,15). In women with genital injuries and blood at the vaginal introitus, further gynaecological investigation is needed to exclude vaginal injuries (15). The potential for significant injury should never be discounted in those patients who also may have blood in the vaginal vault from menstruation. Complete vaginal inspection with specula is mandatory.

6.2.1 Gunshot wounds

In patients with genitalia injured by gunshot wounds, it is very useful to have information about the causative weapon, particularly the range, calibre and type of weapon. High-velocity missiles transmit large amounts of energy to the tissues and can produce trauma to structures outside the wound track. Passage of the missile creates an expansive cavity of subatmospheric pressure, which then collapses and creates shear forces and induction of other foreign bodies and (usually) infected material (1).

6.2.2 Bites

6.2.2.1 Animal bites

Although animal bites are common, bites injuring the external genital are rare. Wounds are usually minor, but have a risk of wound infection. The most common bacterial infection caused by a dog bite is *Pasturella*

multicida, which accounts for up to 50% of infections (16). Other commonly involved organisms are *Escherichia coli*, *Streptococcus viridans*, *Staphylococcus aureus*, *Eikenella corrodens*, *Capnocytophaga canimorsus*, *Veillonella parvula*, *Bacteroides* and *Fusobacterium spp.* (11,16,17).

The first choice of antibiotics is penicillin-amoxiclavulanic acid, followed by doxycycline, cephalosporin or erythromycin for 10-14 days (18-20). The possibility of rabies infection must be considered. If rabies infection is suspected, vaccination should be considered in relation to the geographical location, animal involved, specific nature of the wound and the type of attack (provoked/unprovoked). Besides vaccination, local wound management is an essential part of post-exposure prophylaxis. High-risk patients should be vaccinated with human rabies immunoglobulin and human diploid cell vaccine (21,22).

6.2.2.2 Human bites

Human bites are much less common, but infection should be considered, especially in risk groups. Since transmission of viral diseases may occur, risk assessment should be made. If appropriate, hepatitis B vaccine/immunoglobulin and/or HIV post-exposure prophylaxis should be offered. For further details, see Guidelines for the Management of Human Bite Injuries (23).

6.2.3 Sexual assault

Genital injury is often seen (42%) after sexual abuse, which must be considered when genital injuries present at any age (24). In these cases, the extraordinary emotional situation of the patient must be considered and the privacy of the patient respected. In suspicious cases, gynaecological and forensic support and advice is necessary. Swabs or vaginal smears should be taken for detection of spermatozoa (25) and local legal protocols followed closely. A thorough history and examination (in some cases under anaesthesia), photo documentation, and identification of forensic material may be important. In a recent report, only 38% of the forensic samples tested positive for an ejaculate and/or sperm. This may be due to delayed presentation or lack of vaginal/anal ejaculation (26,27).

6.3 Organ-specific genital trauma

6.3.1 Penile trauma

6.3.1.1 Blunt penile trauma

Blunt trauma to the flaccid penis does not usually cause tearing of the tunica. In these cases, only subcutaneous haematoma with intact tunica albuginea may be seen.

6.3.1.1.1 Penile fracture

The most important and common presentation of blunt penile trauma is penile fracture. This results from trauma to the erect penis during sexual intercourse, masturbation, rolling over in bed (rarely) and as a result of self-inflicted bending to produce detumescence in some Middle Eastern Cultures—a practice known as ‘taqaandan’ (which, when translated, means ‘to click’) (28). The most common mechanism of injury is when the penis slips out of the vagina and strikes against the symphysis pubis or perineum. Sixty per cent of cases occur during consensual intercourse (29), and is more likely when the partner is on top. Penile fracture is caused by rupture of the cavernosal tunica albuginea, and may be associated with subcutaneous haematoma, and lesions of the corpus spongiosum or urethra in 10-22% (30,31).

The thickness of the tunica albuginea in the flaccid state (approximately 2 mm) decreases in erection to 0.25-0.5 mm, and is therefore more vulnerable to traumatic injury (32,33). Penile fracture is associated with a sudden cracking or popping sound, pain and immediate detumescence. Local swelling of the penile shaft develops quickly, due to enlarging haematoma. Bleeding may spread along the fascial layers of the penile shaft and extend to the lower abdominal wall if Buck’s fascia is also ruptured. The rupture of the tunica may be palpable.

A thorough history and examination usually confirm the diagnosis, but in some cases imaging may be useful. Cavemosography, US or MRI (34-36) can identify lacerations of the tunica albuginea in unclear cases (37) or provide reassurance that the tunica is intact. If a concomitant urethral injury is suspected, a retrograde urethrogram (RUG) may be performed but flexible cystoscopy under anaesthesia during exploration/repair is more usually employed.

Subcutaneous haematoma, without associated rupture of the cavernosal tunica albuginea, does not require surgical intervention. In these cases, non-steroidal analgesics and ice-packs are recommended (8). Less severe penile injuries can be distinguished from penile fracture, as they are not usually associated with detumescence.

Early surgical intervention with closure of the tunica albuginea is recommended. The approach is usually made

by a circumferential incision proximal to the coronal sulcus to deglove the penis entirely. Increasingly, local longitudinal incisions centred on the area of fracture are used and further localisation may be gained with a flexible cystoscopy prior to incision if urethral trauma is suspected and proven. Closure can be obtained by using absorbable sutures, with good long-term outcome, and protection of potency. Post-operative complications were reported in 9%, including superficial wound infection and impotence in 1.3% (29,38). The conservative management of penile fracture is not recommended. It increases complications, such as penile abscess, missed urethral disruption, penile curvature, and persistent haematoma requiring delayed surgical intervention (38). Late complications after conservative management were fibrosis and angulations in 35% and impotence in up to 62% (29,38).

6.3.2 **Penetrating penile trauma**

Penetrating penile trauma is rarely seen in isolation. Most cases are associated with multiple injuries. Non-operative management is recommended in small superficial injuries with intact Buck's fascia (8). In more significant penetrating penile injuries, surgical exploration and debridement of necrotic tissue is recommended. Even in extended injuries of the penis, primary alignment of the disrupted tissues may allow for acceptable healing because of the robust penile blood supply (11).

The elasticity of genital skin means it is usually possible to manage the loss of a moderate amount of penile skin. However, management is more difficult in extensive injuries with significant skin loss. The tissue chosen for reconstruction following trauma needs to provide good coverage and must be suitable for reconstruction. Split-thickness skin grafting provides good coverage and a dependable take that is reproducible and durable. However, split-thickness grafts contract more than full-thickness grafts and their use on the penile shaft should be kept to a minimum. McAninch et al. recommended the use of a skin graft thickness of at least 0.015 inch (0.4 mm) in order to reduce the risk of contraction (11). Full-thickness skin grafting onto the penile shaft gives less contracture, a better cosmetic appearance and more resistance to trauma during intercourse, when eventually re-established (39). The donor site may be taken from the abdomen, buttock, thigh or axilla and is chosen according to surgeon preference and injury pattern.

The principles of care are debridement of devitalised tissue, with the preservation of as much viable tissue as possible, haemostasis, diversion of urine in selected cases and the removal of foreign bodies. Tissues of questionable viability may be left for subsequent definitive surgery. Subsequent immediate or delayed repair is needed, depending on the injury and extent of tissue damage, and usually takes place 4-6 weeks after the trauma has occurred.

If there has been extensive destruction of deeper tissues, or if later prosthetic placement is being considered, skin flaps, with their secure vascular supply can be used. The surgical approach will depend upon the site and extent of the injury, but a subcoronal incision with penile degloving usually gives good exposure. Initially, a defect in the tunica albuginea should be closed after copious irrigation. If there has been too much tissue loss, the defect can be repaired either immediately or after delay with a patch (either from an autologous saphenous vein or xenograft). If a concomitant urethral injury is suspected, a pre- or peri-operative urethrogram or cystoscopy is useful to diagnose any urethral involvement, to define its position, and to decide upon the incision used.

6.3.3 **Penile avulsion injuries and amputation**

Most injuries are self-inflicted, but some are a result of industrial accidents or assault. Acute management involves resuscitation of the patient, who may be compromised from blood loss, and preparation for surgical re-implantation of the penis if it has been recovered and is not too badly damaged. Surgical re-implantation should be considered for all patients and should be performed within 24 hours of amputation. If the injury occurred during a psychotic episode, early psychiatric advice and support should be sought.

The severed penis should be washed with sterile saline, wrapped in saline-soaked gauze, placed in a sterile bag and immersed in iced water. The penis must not come into direct contact with the ice. A pressure dressing or a tourniquet should be placed around the penile stump to prevent excessive blood loss. Re-attachment can be achieved in a non-microsurgical way, but this technique probably gives a higher post-operative urethral stricture rate and more problems with loss of sensation (40). Firstly, the corpora cavernosa and urethra are aligned and repaired, and then the dorsal penile arteries, the dorsal vein and the dorsal nerves are repaired with the use of an operating microscope. The cavernosal arteries are generally too small to anastomose. The fascia and skin are closed in layers and both a urethral and a suprapubic catheter are placed.

If the severed penis cannot be found, or is unsuitable for re-attachment, then the end should be closed as if for

a partial penectomy. Later reconstruction may be employed to lengthen the penis (e.g. suspensory ligament division and v-y plasty, pseudo-glans formation with split-thickness skin grafting, etc). A delayed major reconstructive procedure, i.e. phalloplasty (either radial artery or pubic), is sometimes required for injuries which leave very little or no functioning penile stump.

6.4 Scrotal trauma

6.4.1 Blunt scrotal trauma

Blunt trauma to the scrotum can cause testicular dislocation, testicular haematocoele, testicular rupture and/or scrotal haematoma.

6.4.1.1 Testicular dislocation

Traumatic dislocation of the testicle occurs rarely. It is most common in victims of MVAs (41-44). Bilateral dislocation of the testes has been reported in up to 25% of cases (44). It can be either a subcutaneous dislocation with epifascial displacement of the testis or an internal dislocation. In the latter, the testis is positioned in the superficial external inguinal ring, inguinal canal or abdominal cavity. Traumatic dislocation of the testis is treated by manual replacement and secondary orchidopexy. If primary manual reposition cannot be performed, immediate orchidopexy is indicated.

6.4.1.2 Haematocoele

Conservative management is recommended in haematocoeles smaller than three times the size of the contralateral testis (45). In large haematocoeles, non-operative management often fails, and often requires delayed surgery (> 3 days). Patients with large haematocoeles have a higher rate of orchiectomy than patients who undergo early surgery, even in non-ruptured testes (2,11,46-48). Early surgical intervention resulted in preservation of the testis in more than 90% of cases compared to delayed surgery, which resulted in orchiectomy in 45-55% of patients (46). In addition, non-operative management is associated with prolonged hospital stays. Large haematocoeles should be treated surgically, irrespective of testicle contusion or rupture. At the very least, the blood clot should be evacuated from the tunica vaginalis sac to relieve disability and hasten recovery. Patients initially treated non-operatively may need delayed surgery if they develop infection or undue pain.

6.4.1.3 Testicular rupture

Testicular rupture is found in approximately 50% of cases of direct blunt scrotal trauma (46). It may occur under intense, traumatic compression of the testis against the inferior pubic ramus or symphysis, resulting in a rupture of the tunica albuginea of the testis. A force of approximately 50 kg is necessary to cause testicular rupture (49). Testicular rupture is associated with immediate pain, nausea, vomiting, and sometimes fainting. The hemiscrotum is tender, swollen, and ecchymotic. The testis itself may be difficult to palpate.

High-resolution, real-time US with a high-resolution probe (minimum 7.5 MHz or higher) should be performed to determine intra- and/or extra-testicular haematoma, testicular contusion or rupture (50-58). The literature is contradictory as to the usefulness of US compared to clinical examination alone. Some studies have reported convincing results with a specificity of up to 98.6% (59). Others reported poor specificity (78%) and sensitivity (28%) for the differentiation of testicular rupture or haematocoele, while accuracy is as low as 56% (53). Colour Doppler-duplex US may provide useful information when used to evaluate testicular perfusion. If scrotal US is inconclusive, testicular CT or MRI may be helpful (60). However, these techniques did not specifically increase the detection of testicular rupture. It is therefore essential to surgically explore equivocal patients - if imaging studies cannot definitively exclude testicular rupture, surgical exploration is indicated. This involves exploration with evacuation of clot and haematoma, excision of any necrotic testicular tubules and closure of the tunica albuginea, usually with running absorbable sutures (e.g. 3/0 Vicryl).

6.4.2 Penetrating scrotal trauma

Penetrating injuries to the scrotum require surgical exploration with conservative debridement of non-viable tissue. Depending on the extent of the injury, primary reconstruction of testis and scrotum can usually be performed. In complete disruption of the spermatic cord, realignment without vaso-vasostomy may be considered if surgically feasible (61). Staged secondary microsurgical vaso-vasostomy can be performed after rehabilitation, although only a few cases have been reported (61). If there is extensive destruction of the tunica albuginea, mobilization of a free tunica vaginalis flap can be performed for testicular closure. If the patient is unstable or reconstruction cannot be achieved, orchiectomy is indicated.

Prophylactic antibiotics are recommended after scrotal penetrating trauma, although data to support this approach is lacking. Tetanus prophylaxis is mandatory. Post-operative complications were reported in 8% of

patients who underwent testicular repair after penetrating trauma (8).

Extended laceration of scrotal skin requires surgical intervention for skin closure. Due to the elasticity of the scrotum, most defects can be primarily closed, even if the lacerated skin is only minimally attached to the scrotum (11). Local wound management with extensive initial wound debridement and washout is important for scrotal convalescence.

In case of extensive loss of genital tissue, e.g. IED blast injury, complex and staged reconstructive surgical procedures are often required (9).

6.5 Genital trauma in females

In females with blunt trauma to the external genitalia, imaging studies of the pelvis with US, CT, or MRI should be performed since additional injuries and extensive intrapelvic haematoma are frequently found (15,25).

6.5.1 Blunt vulvar injuries

Blunt trauma to the vulva is rarely reported and usually presents as a large haematoma. The incidence of traumatic vulvar haematomas after vaginal deliveries has been reported as 1 in 310 deliveries (62). Although blunt trauma to the female external genitalia is rarely reported, the presence of a vulvar haematoma is closely related to an increased risk of associated vaginal, pelvic or abdominal injuries. Goldman et al. reported that blunt injuries of the vulva and vagina were associated with pelvic trauma in 30%, after consensual intercourse in 25%, sexual assault in 20%, and other blunt trauma in 15% (14).

Blunt vulvar or perineal trauma may be associated with voiding problems and bladder catheterization is usually required. Vulvar haematomas usually do not require surgical intervention, although they can cause significant blood loss, even sometimes requiring red blood cell transfusions. Data are scarce (64), but in haemodynamically stable women, non-steroidal anti-inflammatory medication and cold packs are used. In massive vulvar haematoma or haemodynamically unstable patients, surgical intervention, lavage and drainage is indicated (65).

Although antibiotics are recommended after major vulvar trauma, there is no data to support this approach. It is important to emphasise that vulvar haematoma and/or blood at the vaginal introitus are an indication for vaginal exploration under sedation or general anaesthesia. The aim is to identify possible associated vaginal and/or rectal injuries (15). Flexible or rigid cystoscopy has been recommended to exclude urethral and bladder injury (14,15). In case of vulvar laceration, suturing after conservative debridement is indicated. If there are associated injuries to the vagina, these can be repaired immediately by primary suturing.

6.6 Conclusion and recommendations for genital trauma

| Conclusion | LE |
|--|----|
| Most genital injuries, in males and females, are caused by blunt trauma. | 3 |

| Recommendations | GR |
|---|----|
| In penile fracture, early surgical management, with closure of tunica albuginea, is recommended to enable good long-term outcome and preservation of potency. | B |
| In testicular trauma, surgical exploration is recommended in all cases of testicular rupture and in those with equivocal imaging. | B |

6.7 References

- Brandes SB, Buckman RF, Chelsky MJ, et al. External genitalia gunshot wounds: a ten-year experience with fifty-six cases. *J Trauma* 1995 Aug;39(2):266-71.
<http://www.ncbi.nlm.nih.gov/pubmed/7674395>
- Monga M, Hellstrom WJ. Testicular Trauma. *Adolesc Med* 1996 Feb;7(1):141-148.
<http://www.ncbi.nlm.nih.gov/pubmed/10359963>
- Frauscher F, Klauser A, Stenzl A, et al. US findings in the scrotum of extreme mountain bikers. *Radiology* 2001 May;219(2):427-31.
<http://www.ncbi.nlm.nih.gov/pubmed/11323467>
- de Peretti F, Cambas PM, Veneau B, et al. [Fuel tanks of motorcycles. Role in severe trauma of the pelvis.] *Presse Med* 1993 Jan;22(2):61-3. [Article in French]
<http://www.ncbi.nlm.nih.gov/pubmed/8493205>

5. Herrmann B, Crawford J. Genital injuries in prepubertal girls from inline skating accidents. *Pediatrics* 2002 Aug;110(2 Pt 1):e16.
<http://www.ncbi.nlm.nih.gov/pubmed/12165615>
6. Lawson JS, Rotem T, Wilson SF. Catastrophic injuries to the eyes and testicles in footballers. *Med J Aust* 1995 Sep;163(5):242-4.
<http://www.ncbi.nlm.nih.gov/pubmed/7565208>
7. Selikowitz SM. Penetrating high-velocity genitourinary injuries. Part I. Statistics mechanism and renal wounds. *Urology* 1977 Apr;9(4):371-6.
<http://www.ncbi.nlm.nih.gov/pubmed/855062>
8. Phonsombat S, Master VA, McAninch JW. Penetrating external genitalia trauma: a 30-year single institution experience. *J Urol* 2008 Jul;180(1):192-5.
<http://www.ncbi.nlm.nih.gov/pubmed/18499189>
9. Hudak SJ, Hakim S. Operative management of wartime genitourinary injuries at Balad Air Force Theater Hospital, 2005 to 2008. *J Urol* 2009 Jul;182(1):180-3.
<http://www.ncbi.nlm.nih.gov/pubmed/19450817>
10. Cass AS, Ferrara L, Wolpert J, et al. Bilateral testicular injury from external trauma. *J Urol* 1988 Dec;140(6):1435-6.
<http://www.ncbi.nlm.nih.gov/pubmed/3193512>
11. McAninch JW, Kahn RI, Jeffrey RB, et al. Major traumatic and septic genital injuries. *J Trauma* 1984 Apr;24(4):291-8.
<http://www.ncbi.nlm.nih.gov/pubmed/6368854>
12. Michielsen D, Van Hee R, Neetens C, et al. Burns to the genitalia and the perineum. *J Urol* 1998 Feb;159(2):418-9.
<http://www.ncbi.nlm.nih.gov/pubmed/9649253>
13. Nelius T, Armstrong ML, Rinard K, et al. Genital piercings: diagnostic and therapeutic implications for urologists. *Urology* 2011 Nov;78(5):998-1007.
<http://www.ncbi.nlm.nih.gov/pubmed/22054364>
14. Goldman HB, Idom CB Jr, Dmochowski RR. Traumatic injuries of the female external genitalia and their association with urological injuries. *J Urol* 1998 Mar;159(3):956-9.
<http://www.ncbi.nlm.nih.gov/pubmed/9474191>
15. Husmann DA. Editorial Comment. *J Urol* 1998;159:959
16. Donovan JF, Kaplan WE. The therapy of genital trauma by dog bite. *J Urol* 1989 May;141(5):1163-5.
<http://www.ncbi.nlm.nih.gov/pubmed/2651716>
17. Presutti RJ. Prevention and treatment of dog bites. *Am Fam Physician* 2001 Apr; 63(8):1567-72.
<http://www.ncbi.nlm.nih.gov/pubmed/11327433>
18. Lewis KT, Stiles M. Management of cat and dog bites. *Am Fam Physician* 1995 Aug;52(2):479-85, 489-90.
<http://www.ncbi.nlm.nih.gov/pubmed/7625323>
19. Presutti RJ. Bite wounds. Early treatment and prophylaxis against infectious complications. *Postgrad Med* 1997 Apr;101(4):243-4, 246-52, 254.
<http://www.ncbi.nlm.nih.gov/pubmed/9126216>
20. Talan DA, Citron DM, Abrahamian FM, et al. Bacteriologic analysis of infected dog and cat bites. Emergency Medicine Animal Bite Infection Study Group. *N Engl J Med* 1999 Jan;340(2):85-92.
<http://www.ncbi.nlm.nih.gov/pubmed/9887159>
21. Dreesen DW, Hanlon CA. Current recommendations for the prophylaxis and treatment of rabies. *Drugs* 1998 Nov;56(5):801-9.
<http://www.ncbi.nlm.nih.gov/pubmed/9829154>
22. Anderson CR. Animal bites. Guidelines to current management. *Postgrad Med* 1992 Jul;92(1):134-6, 139-46, 149.
<http://www.ncbi.nlm.nih.gov/pubmed/1614928>
23. Guidelines for the Management of Human Bite Injuries. Health Protection Agency North West 2007.
http://www.hpa.org.uk/web/HPAwebFile/HPAweb_C/1194947350692
24. McGregor MJ, Du Mont J, Myhr TL. Sexual assault forensic medical examination: is evidence related to successful prosecution? *Ann Emerg Med* 2002 Jun;39(6):639-47.
<http://www.ncbi.nlm.nih.gov/pubmed/12023707>
25. Okur H, Küçükaydin M, Kazez A, et al. Genitourinary tract injuries in girls. *Br J Urol* 1996 Sep;78(3):446-9.
<http://www.ncbi.nlm.nih.gov/pubmed/8881959>

26. Dardamissis E, Gee A, Kaczmarek E, et al on behalf of the North West Policy Group. Guidance for healthcare professionals on dealing with injuries where teeth break the skin. Health Care Protection Agency, October 2007.
http://www.hpa.org.uk/web/HPAwebFile/HPAweb_C/1194947350692
27. A national protocol for sexual assault medical forensic examinations adults/adolescents. U.S. Dept of Justice. Office on Violence Against Women, September 2004.
<http://www.ncjrs.gov/pdffiles1/ovw/206554.pdf>
28. Zargooshi J. Penile fracture in Kermanshah, Iran: report of 172 cases. J Urol 2000 Aug;164(2):364-6.
<http://www.ncbi.nlm.nih.gov/pubmed/10893586>
29. Haas CA, Brown SL, Spirnak JP. Penile fracture and testicular rupture. World J Urol 1999 Apr;17(2):101-6.
<http://www.ncbi.nlm.nih.gov/pubmed/10367369>
30. Nicolaisen GS, Melamud A, Williams RD, et al. Rupture of the corpus cavernosum: surgical management. J Urol 1983 Nov;130(5):917-9.
<http://www.ncbi.nlm.nih.gov/pubmed/6632099>
31. Tsang T, Demby AM. Penile fracture with urethral injury. J Urol 1992 Feb;147(2):466-8.
<http://www.ncbi.nlm.nih.gov/pubmed/1732623>
32. Mydlo JH, Hayyeri M, Macchia RJ. Urethrography and cavernosography imaging in a small series of penile fractures: a comparison with surgical findings. Urology 1998 Apr;51(4):616-9.
<http://www.ncbi.nlm.nih.gov/pubmed/9586616>
33. Lee SH, Bak CW, Choi MH, et al. Trauma to male genital organs: a 10-year review of 156 patients, including 118 treated by surgery. BJU Int 2008 Jan;101(2):211-5.
<http://www.ncbi.nlm.nih.gov/pubmed/17922859>
34. Karadeniz T, Topsakal M, Ariman A, et al. Penile fracture: differential diagnosis, management and outcome. Br J Urol 1996 Feb;77(2):279-81.
<http://www.ncbi.nlm.nih.gov/pubmed/8800899>
35. Pretorius ES, Siegelman ES, Ramchandani P, et al. MR imaging of the penis. Radiographics 2001 Oct;21 Spec No:S283-98, discussion S298-9.
<http://www.ncbi.nlm.nih.gov/pubmed/11598264>
36. Fedel M, Venz S, Andreessen R, et al. The value of magnetic resonance imaging in the diagnosis of suspected penile fracture with atypical clinical findings. J Urol 1996 Jun;155(6):1924-7.
<http://www.ncbi.nlm.nih.gov/pubmed/8618289>
37. Uder M, Gohl D, Takahashi M, et al. MRI of penile fracture: diagnosis and therapeutic follow-up. Eur Radiol 2002 Jan;12(1):113-20.
<http://www.ncbi.nlm.nih.gov/pubmed/11868085>
38. Orvis BR, McAninch JW. Penile rupture. Urol Clin North Am 1989 May;16(2):369-75.
<http://www.ncbi.nlm.nih.gov/pubmed/2652861>
39. Summerton DJ, Campbell A, Minhas S, et al. Reconstructive surgery in penile trauma and cancer. Nat Clin Pract Urol 2005 Aug;2(8):391-7.
<http://www.ncbi.nlm.nih.gov/pubmed/16474736>
40. Babaei AR, Safarinejad MR. Penile replantation, science or myth? A systematic review. Urol J 2007 Spring;4(2):62-5.
<http://www.ncbi.nlm.nih.gov/pubmed/17701923>
41. Lee JY, Cass AS, Streitz JM. Traumatic dislocation of testes and bladder rupture. Urology 1992 Dec;40(6):506-8.
<http://www.ncbi.nlm.nih.gov/pubmed/1466102>
42. Shefi S, Mor Y, Dotan ZA, et al. Traumatic testicular dislocation: a case report and review of published reports. Urology 1999 Oct;54(4):744.
<http://www.ncbi.nlm.nih.gov/pubmed/10754145>
43. Pollen JJ, Funckes C. Traumatic dislocation of the testes. J Trauma 1982 Mar;22(3):247-9.
<http://www.ncbi.nlm.nih.gov/pubmed/7069812>
44. Nagarajan VP, Pranikoff K, Imahori SC, et al. Traumatic dislocation of testis. Urology 1983 Nov;22(5):521-4.
<http://www.ncbi.nlm.nih.gov/pubmed/6649208>
45. Tiguert R, Harb JF, Hurley PM, et al. Management of shotgun injuries to the pelvis and lower genitourinary system. Urology 2000 Feb;55(2):193-7.
<http://www.ncbi.nlm.nih.gov/pubmed/10688077>
46. Cass AS, Luxenberg M. Testicular injuries. Urology 1991 Jun;37(6):528-30.
<http://www.ncbi.nlm.nih.gov/pubmed/2038785>

47. Altarac S. Management of 53 cases of testicular trauma. *Eur Urol* 1994;25(2):119-23.
<http://www.ncbi.nlm.nih.gov/pubmed/8137851>
48. Cass AS, Luxenberg M. Value of early operation in blunt testicular contusion with hematocele. *J Urol* 1988 Apr;139(4):746-7.
<http://www.ncbi.nlm.nih.gov/pubmed/3352037>
49. Wasko R, Goldstein AG. Traumatic rupture of the testicle. *J Urol* 1966 May;95(5):721-3.
<http://www.ncbi.nlm.nih.gov/pubmed/5935538>
50. Pavlica P, Barozzi L. Imaging of the acute scrotum. *Eur Radiol* 2001;11(2):220-8.
<http://www.ncbi.nlm.nih.gov/pubmed/11218018>
51. Micallef M, Ahmad I, Ramesh N, et al. Ultrasound features of blunt testicular injury. *Injury* 2001 Jan;32(1):23-6.
<http://www.ncbi.nlm.nih.gov/pubmed/11164397>
52. Patil MG, Onuora VC. The value of ultrasound in the evaluation of patients with blunt scrotal trauma. *Injury* 1994 Apr;25(3):177-8.
<http://www.ncbi.nlm.nih.gov/pubmed/8168890>
53. Corrales JG, Corbel L, Cipolla B, et al. Accuracy of ultrasound diagnosis after blunt testicular trauma. *J Urol* 1993 Dec;150(6):1834-6.
<http://www.ncbi.nlm.nih.gov/pubmed/8080482>
54. Mulhall JP, Gabram SG, Jacobs LM. Emergency management of blunt testicular trauma. *Acad Emerg Med* 1995 Jul;2(7):639-43.
<http://www.ncbi.nlm.nih.gov/pubmed/8521212>
55. Martinez-Piñero L Jr, Cerezo E, Cozar JM, et al. Value of testicular ultrasound in the evaluation of blunt scrotal trauma without haematocele. *Br J Urol* 1992 Mar;69(3):286-90.
<http://www.ncbi.nlm.nih.gov/pubmed/1568102>
56. Fournier GR Jr, Laing FC, McAninch JW. Scrotal ultrasonography and the management of testicular trauma. *Urol Clin North Am* 1989 May;16(2):377-85.
<http://www.ncbi.nlm.nih.gov/pubmed/2652862>
57. Kratzik C, Hainz A, Kuber W, et al. Has ultrasound influenced the therapy concept of blunt scrotal trauma? *J Urol* 1989 Nov;142(5):1243-6.
<http://www.ncbi.nlm.nih.gov/pubmed/2681835>
58. Andipa E, Liberopoulos K, Asvestis C. Magnetic resonance imaging and ultrasound evaluation of penile and testicular masses. *World J Urol* 2004 Nov;22(5):382-91.
<http://www.ncbi.nlm.nih.gov/pubmed/15300391>
59. Lee SH, Bak CW, Choi MH, et al. Trauma to male genital organs: a 10-year review of 156 patients, including 118 treated by surgery. *BJU Int* 2008 Jan;101(2):211-5.
<http://www.ncbi.nlm.nih.gov/pubmed/17922859>
60. Muglia V, Tucci S Jr, Elias J Jr, et al. Magnetic resonance imaging of scrotal diseases: when it makes the difference. *Urology* 2002 Mar;59(3):419-23.
<http://www.ncbi.nlm.nih.gov/pubmed/11880084>
61. Altarac S. A case of testicle replantation. *J Urol* 1993 Nov;150(5 Pt 1):1507-8.
<http://www.ncbi.nlm.nih.gov/pubmed/8411440>
62. Sotto LS, Collins RJ. Perigenital Hematomas; analysis of forty-seven consecutive cases. *Obstet Gynecol* 1958 Sep;13:259-63.
<http://www.ncbi.nlm.nih.gov/pubmed/13578292>
63. Propst AM, Thorp JM Jr. Traumatic vulvar hematomas: conservative versus surgical management. *South Med J* 1998 Feb;91(2):144-6.
<http://www.ncbi.nlm.nih.gov/pubmed/9496865>
64. McWilliams GD, Hill MJ, Dietrich CS 3rd. Gynecologic emergencies. *Surg Clin North Am* 2008 Apr;88(2):265-83.
<http://www.ncbi.nlm.nih.gov/pubmed/18381113>
65. Virgili A, Bianchi A, Mollica G, et al. Serious hematoma of the vulva from a bicycle accident. A case report. *J Reprod Med* 2000 Aug;45(8):662-4.
<http://www.ncbi.nlm.nih.gov/pubmed/10986686>

7. POLYTRAUMA, DAMAGE CONTROL AND MASS CASUALTY EVENTS

7.1 Introduction

Urological trauma is often associated with significant and higher priority injuries in the polytraumatised patient (1). Lessons from civilian trauma networks, the battlefield, and mass casualty events have led to many advances in general trauma care (2,3). These include the widespread acceptance of damage control principles, trauma centralisation and recognition of the value of dedicated trauma teams. Urologists need to understand their role in the context of polytrauma with the ultimate aims of improving survivability and decreasing morbidity in these patients.

7.1.1 The development of major trauma centres

Multidisciplinary management of trauma patients has been shown to improve outcomes (4). Major trauma patients initially managed in local hospitals are 1.5 to 5 times more likely to die than patients transported directly to specialist trauma centres. The rationalisation of care to these centres has been shown to reduce mortality by 25% and length of stay by four days (2). Major trauma centres are expected to provide senior-led resuscitative trauma teams, dedicated trauma theatres, input from all major surgical specialties, interventional radiology and have been established worldwide. Urologists have an important role to play in this process (5).

7.1.1.1 Recommendations for polytrauma management

| | LE | GR |
|---|----|----|
| Polytrauma patients are ideally managed in designated major trauma centres. | 3 | A |
| Urologists are to be involved in cases of associated urological injury. | 4 | A |

7.2 Damage control

Damage control is a life-saving strategy for severely injured patients that recognises the consequences of the lethal triad of trauma, i.e. hypothermia, coagulopathy and acidosis (6-8).

It is a prioritised three-phase approach:

- The first phase consists of rapid control of haemorrhage and wound contamination.
- The second phase involves resuscitation in the intensive care unit (ICU), with the goal of restoring normal temperature, coagulation, and tissue oxygenation.
- The third stage involves definitive surgery when more time-consuming reconstructive procedures are performed in the stabilised patient (9).

Identifying which patients benefit from the damage control mode requires critical decision-making by the trauma team leader. Preparation and regular communication between the surgical, critical care and anaesthetic teams is vital (10). Damage control principles have been successfully adopted in the context of civilian mass casualty events, military field surgery, and initial treatment in rural areas with long-range transfers (8,11).

7.3 Management principles: polytrauma and associated urological injury

Urologists are often asked for advice in polytrauma patients, some of whom might be in a damage control phase of management. Fortunately, the management of urological trauma often involves the use of temporary measures, followed by later definitive surgery, which fits in well with these principles.

In the polytrauma setting, the urologist will usually work alongside the general/trauma surgeon. Procedures should be directed at the rapid control of bleeding, debridement of dead and devitalised tissue, and minimising urinary extravasation by simple diversionary measures. Complex reconstructive procedures, including organ preservation, are preferably delayed.

Examples where urological input is required in the polytraumatised patient include:

- Haemodynamically unstable patients with suspected intra-abdominal bleeding, who are transferred urgently to the operating theatre without any pre-operative imaging;
- Stable patients with suspected renal injuries-penetrating trauma to the upper abdomen/flanks/lower chest, or blunt abdominal trauma and gross haematuria;
- Patients with suspected urethral or bladder injury associated with pelvic fractures-blood at the urethral meatus and/or the inability to void;
- External genitalia injury associated with penetrating trauma (intra-abdominal injury).

7.3.1 **Statement and recommendation on management principles**

| Statement | LE | GR |
|---|----|----|
| Damage control principles govern the management of the severely injured polytrauma patient. | 4 | |
| Recommendation | | |
| Urologists are to understand their role in the damage control setting. | 4 | A |

7.4 **Urological injury management in polytrauma**

7.4.1 **Renal injury**

The incidence of multiorgan injury is particularly high (94.6%) in penetrating trauma (12). Most of these injuries can be managed without surgical exploration (13). Renal exploration is required to control life-threatening bleeding (14). The preservation of viable renal parenchyma is a secondary goal, with time-consuming renal reconstruction delayed until the patient is optimised (15).

At laparotomy, it is considered best practice not to explore the injured kidney if there is no active haemorrhage, even if delayed exploration is then necessary (16). In unstable patients, packing the renal fossa and transferring the patient to the surgical ICU is the option of choice for damage control. A planned second-look laparotomy is then performed (17). However, in patients with significant ongoing haemorrhage, speedy nephrectomy is required. It is recommended that the contralateral kidney should at least be palpated prior to nephrectomy (18).

In patients who are packed temporarily and who become sufficiently stable in the intensive setting, radiological assessment allows definitive management to begin. Computed tomography allows the kidney injury to be graded, documents the presence of a contralateral kidney, and helps to determine whether or not intervention (radiological or surgical) is necessary.

In patients who are haemodynamically unstable after the initial, acute-damage-control, laparotomy, or in patients with deteriorating haemodynamic parameters (indicating ongoing or delayed bleeding), the management options are angiographic embolisation of the bleeding kidney or re-operation. This decision should be made according to:

- The status of the patient;
- The presence of associated injuries (stapled bowel, packed liver or spleen), which may need re-operation irrespective of the renal injury;
- The availability of angioembolisation.

7.4.1.1 **Renal preservation**

Haemostatic techniques, many of which were developed for hepatic surgery and splenic trauma, can be used to control renal parenchymal bleeding. These techniques are not consistent with damage control principles and should only be considered in the rare casualty situation of a solitary kidney or bilateral renal injury.

These techniques are outlined below:

- Mattress sutures through the parenchyma, i.e. Renorrhaphy (17).
- Haemostatic agents, i.e. Combined acellular matrix and fibrin sealants (19).
- Absorbable mesh kidney bags to maintain contact between renal parenchymal fragments (20).
- An intra-operative drain is left in situ to collect any urine that leaks following organ salvage.

7.4.1.2 **Recommendations for the management of renal injury**

| | LE | GR |
|---|----|----|
| Life-threatening bleeding from renal injury is best managed by urgent nephrectomy. | 4 | B |
| Renal packing is an acceptable damage control option for haemorrhage. | 4 | B |
| Angioembolisation can be used immediately or can be delayed as a very effective haemostatic option. | 4 | B |
| Renal preservation is reserved primarily for patients with a solitary kidney. | 4 | B |

7.4.2 **Ureteral injury**

Ureteral injuries are primarily associated with penetrating intra-abdominal injury; although rapid deceleration injuries can also result in ureteropelvic disruption (21). A high index of suspicion is required as these injuries are quite commonly missed (22). The results of immediate ureteral reconstruction are generally satisfactory, but this is time consuming and may not be appropriate in the polytraumatised patient. Diagnostic procedures, such as on-table IVP or retrograde ueretryelography, to evaluate ureteral injuries are also not recommended in this setting.

If a ureteral injury is suspected but not clearly identified, a drain should be sited. If urine leaks post operatively, a nephrostomy should be arranged. If a partial ureteral tear is identified (less than half a circumference) and the ureter is otherwise healthy, a double J-stent may be inserted over a guide wire through the tear, and the tear quickly closed with fine interrupted absorbable stitches.

When complete ureteral injuries are identified, definitive repair should not be performed. Dissection of the ureteral stumps should be avoided as it interferes with the blood supply. Temporary measures to control urine spillage should be performed:

- A single j or 8 french feeding tube is inserted into the ureter;
- The end of the disrupted proximal ureter is secured over the tube, which is exteriorised and secured to the skin.

The distal ureteral stump does not need to be ligated and any unnecessary manipulation should be avoided. Intra-operative placement of a nephrostomy tube is time-consuming and should be avoided (15,17).

Tying off the injured ureteral segment and inserting a percutaneous nephrostomy post-operatively is a viable alternative (23). Rarely, in cases with severe associated injuries of the ipsilateral kidney, nephrectomy is required.

7.4.2.1 Recommendations for the management of ureteral injury

| | LE | GR |
|--|----|----|
| A high index of suspicion for ureteral injury in penetrating abdominal trauma is required. | 4 | A |
| Simple 'tube' urinary diversion is recommended if repair is not undertaken. | 4 | C |

7.4.3 Bladder trauma

In the acute polytrauma setting, a bladder injury should be treated with bladder drainage by a suprapubic and/or a urethral catheter. Later, definitive treatment can follow as necessary (24). Ideally, large intraperitoneal bladder ruptures (often associated with unstable pelvic fractures) should be closed primarily and drained, as this will cope with both haemorrhage control and urinary contamination.

Examples of temporary measures that may be necessary include:

- The placement of externalised ureteral stents to provide external urinary drainage in extensive bladder rupture (17);
- Packing and/or arteriography and selective embolisation in unstable patients with severe bladder haemorrhage (17);
- The placement of a pelvic suction drain for urinary evacuation (17).

7.4.3.1 Recommendations for the management of bladder trauma

| | LE | GR |
|--|----|----|
| Bladder injuries require urinary drainage by either the suprapubic or urethral route. | 4 | A |
| Complex bladder injuries in the setting of polytrauma may require temporary 'damage control' measures. | 4 | A |

7.4.4 Urethral injury

Urethral injury of any kind is not life-threatening, but the associated injuries are often severe. In this situation, wherever the location or extent of injury, drainage through a suprapubic or urethral catheter should be obtained without prior imaging (25).

7.4.4.1 Recommendation for the management of urethral injury

| | LE | GR |
|---|----|----|
| Urethral injuries require urgent urinary drainage by either the suprapubic or urethral route. | 4 | A |

7.4.5 External genital injury

Traditionally, traumatic injuries of the external genitalia have a low priority and management is often deferred (26). In the polytraumatised patient, the management of these injuries should be guided by the principles of haemorrhage control, debridement and urinary diversion (via a catheter). Delayed organ conservation is possible, particularly in testicular injury (27).

Temporary damage control measures that might be applicable include:

- Compression dressing of the penis (17);
- Packing of penetrating testicular injuries;
- Tampons for vulvar lacerations.

7.5 Mass casualty events

A mass casualty event is one in which the number of injured people is significantly higher than the number of available healthcare providers (28). A mass casualty disaster does not therefore necessarily involve a large number of victims, but it is related to the disproportion between the number of victims and the size of the medical team available (29,30).

There is little published data on the best way in which to handle these events. However, recent developments in both the military and civilian settings have led to greater survivability following major trauma (31). Triage, communication and preparedness are important components for a successful response.

Potential mass casualty events include:

- Transportation systems accidents, e.g. Road traffic, aircraft, shipping, railways;
- Natural disasters, e.g. Earthquakes, hurricanes, floods, tsunamis;
- Industry, e.g. Chemical spills, factory explosions and fires;
- Civilian terrorism.

7.5.1 Triage

Triage after mass casualty events is difficult and involves difficult moral and ethical considerations. Disaster triage requires differentiation of the few critically injured individuals who can be saved by immediate intervention from the many others with non-life-threatening injuries for whom treatment can be delayed. The ethical dilemmas that arise are primarily caused by having to decide who should be actively treated, or subsequently whether to stop treatment, because of injuries deemed unsurvivable or incompatible with survival in the home environment.

Triage sorts patients into four groups (32,33):

1. Patients with life-threatening injuries that require immediate intervention, presenting with airway compromise, breathing failure and/or circulatory compromise from ongoing external haemorrhage.
2. Patients with severe but non-life-threatening injuries, in whom treatment can be acceptably delayed, including those with major fractures, vascular injuries of the limbs and large soft tissue wounds.
3. 'Walking wounded', i.e. casualties with minimal injuries.
4. Patients who are so severely injured that treatment would require allocation of resources and time that would deny timely care to other patients with greater survivability. These patients are given minimal or no treatment, and are re-evaluated when resources become available. There is no absolute definition for this group because triage is individualised, according to the number and severity of casualties related to the available resources. The decision to implement this category is decided when sufficient information of the incident is available and is made at the highest level possible.

Triage should be performed at each stage from the pre-hospital setting to the emergency department and repeated as the clinical situation evolves. Ultimately, the individual in charge is responsible for directing specialty surgical teams, including urologists, and assigning them responsibility for specific patients as dictated by the specific injuries.

7.5.2 Urological role in the mass casualty setting

Urological consultations during a mass casualty scenario should follow the principles outlined below:

1. Rule out under-triage by the surgeon in charge, and perform a rapid primary survey of every patient.
2. Avoid unnecessary imaging procedures such as CT scans and retrograde urethrography. These procedures should be performed later, after re-evaluation of the patient, and after mass casualty protocols have been suspended.
3. Treat unstable patients who are to have surgery using damage control principles.
4. Stable patients should be transferred to the surgical ward without imaging procedures. Re-evaluate if there is any change in their haemodynamic status, or when possible as dictated by the constraints of the mass casualty event.
5. 'Minimal acceptable' treatment for all urological injury should be performed in order to transfer patients to the surgical wards and are outlined above in the Section 7.4 Urological injury management in polytrauma.

7.5.3 Statements and recommendations for mass casualty events

| Statements | LE |
|--|----|
| Recent large scale military conflicts have raised the standard of practice for trauma patients. | 4 |
| The centralisation of trauma and the establishment of trauma centres results in better outcomes for trauma patients. | 3 |
| Urologists have an important role to play in the management of polytrauma patients. | 4 |
| Recommendations | GR |
| Damage control surgery should be employed as the standard approach in the management of unstable trauma patients. | A |
| Medical teams should be well prepared to deal with polytrauma events. | A |
| All surgical sub-specialists involved in trauma management should be very familiar with the principles of triage and damage control. | A |

7.6 References

1. Monstrey SJ, vander Werken C, Debryne FM, et al. Urological trauma and severe associated injuries. *Br J Urol* Nov 1987 Nov;60(5):393-8.
<http://www.ncbi.nlm.nih.gov/pubmed/3427315>
2. Mackenzie E, Rivara FP, Jurkovich GJ, et al. A National Evaluation of the Effect of Trauma-Center Care on Mortality. *N Engl J Med* 2006 Jan;354(4):366-378.
<http://www.ncbi.nlm.nih.gov/pubmed/16436768>
3. Catterson EJ, Carty MJ, Weaver, et al. Boston Bombings: a surgical view of lessons learnt from combat Casualty care and the applicability to Boston's terrorist attack. *J Craniofac Surg* 2013 Jul; 24(4):1061-7.
<http://www.ncbi.nlm.nih.gov/pubmed/23851738>
4. Dutton RP, Cooper C, Jones A, et al. Multidisciplinary rounds shorten length of stay for trauma patients. *J Trauma* 2003 Nov;55(5):913-9.
<http://www.ncbi.nlm.nih.gov/pubmed/14608165>
5. Makanjuola JK, Grange PC, Kooiman G, et al. Centralisation of major trauma: an opportunity for acute urology services in the UK. *BJU Int* 2012 Jan;109(2):173-4. [No abstract available]
<http://www.ncbi.nlm.nih.gov/pubmed/22212283>
6. Feliciano DV, Moore EE, Mattox KL. Trauma damage control. In: Mattox KL, Feliciano DV, Moore EE(eds). *Trauma*, 4th edn, New York: McGraw-Hill, 2000, Chapter 39, pp. 907-931.
7. Hirshberg A, Mattox KL. 'Damage control' in trauma surgery. *Br J Surg* 1993 Dec;80(12):1501-2.
<http://www.ncbi.nlm.nih.gov/pubmed/8298911>
8. Rignault DP. Recent progress in surgery for the victims of disaster, terrorism, and war--Introduction. *World J Surg* 1992 Sep-Oct;16(5):885-7.
<http://www.ncbi.nlm.nih.gov/pubmed/1462624>
9. Rotondo MF, Schwab CW, McGonigal MD, et al. 'Damage control': an approach for improved survival in exsanguinating penetrating abdominal injury. *J Trauma* 1993 Sep;35(3):375-82.
<http://www.ncbi.nlm.nih.gov/pubmed/8371295>
10. Mercer SJ, Whittle CL, Mahoney PF. Lessons from the battlefield: human factors in defence anaesthesia. *Br J Anaesth* 2010 Jul;105(1):9-20.
<http://www.ncbi.nlm.nih.gov/pubmed/20551025>
11. Holcomb JB, Helling TS, Hirshberg A. Military, civilian and rural application of the damage control philosophy. *Mil Med* 2001 Jun;166(6):490-3.
<http://www.ncbi.nlm.nih.gov/pubmed/11413725>
12. Kansas BT, Eddy MJ, Mydlo JH, Uzzo RG. Incidence and Management of penetrating renal trauma in patients with multiorgan injury: extended experience at an inner city trauma centre. *J Urol* 2004 Oct; 172(4 Pt 1):1355-60
<http://www.ncbi.nlm.nih.gov/pubmed/15371841>
13. Santucci RA, Fisher MB. The literature increasingly supports expectant (conservative) management of renal trauma--a systematic review. *J Trauma* 2005 Aug;59(2):493-503
<http://www.ncbi.nlm.nih.gov/pubmed/16294101>
14. Brandes SB, McAninch JW. Renal trauma: a practical guide to evaluation and management. *ScientificWorldJournal* 2004 Jun;4 Suppl 1:31-40.
<http://www.ncbi.nlm.nih.gov/pubmed/15349524>

15. Brandes SB, McAninch JW. Reconstructive surgery for trauma of the upper urinary tract. *Urol Clin North Am* 1999 Feb;26(1):183-99.
<http://www.ncbi.nlm.nih.gov/pubmed/10086060>
16. Wessells H, McAninch JW, Meyer A, et al. Criteria for nonoperative treatment of significant penetrating renal lacerations. *J Urol* 1997 Jan;157(1):24-7.
<http://www.ncbi.nlm.nih.gov/pubmed/8976207>
17. Coburn M. Damage control for urologic injuries. *Surg Clin N Am* 2013 Aug;77:343-350.
<http://www.ncbi.nlm.nih.gov/pubmed/9291984>
18. Hirshberg A, Mattox KL. *Top Knife: the Art and Craft of Trauma Surgery*. TFM Publishing Limited 2005, Chapter 7, pp. 107-112.
19. Shekarris B, Stoller ML. The use of fibrin sealant in urology. *J Urol* 2002 Mar;167(3):1218-25.
<http://www.ncbi.nlm.nih.gov/pubmed/11832701>
20. Chaabouni MN, Bittard M. [Application of peri-renal prosthesis (vicryl mesh) in the conservativetreatment of multiple ruptured kidney fragments.] *Ann Urol* 1996;30(2):61-3. [Article in French]
<http://www.ncbi.nlm.nih.gov/pubmed/8767808>
21. Brandes S, Coburn M, Armenakas N, et al. Diagnosis and management of ureteric injury: an evidence based analysis. *BJU Int* 2004 Aug;94(3):277-89.
<http://www.ncbi.nlm.nih.gov/pubmed/15291852>
22. Best CD, Petrone P, Buscarini M, et al. Traumatic ureteral injuries: a single institution experience validating the American Association for the Surgery of Trauma–Organ Injury Scale grading scale. *J Urol* 2005 Apr;173(4):1202-5.
<http://www.ncbi.nlm.nih.gov/pubmed/15758748>
23. Hirshberg A, Wall MJ Jr, Mattox KL. Planned reoperation for trauma: a two year experience with 124 consecutive patients. *J Trauma* 1994 Sep;37(3):365-9.
<http://www.ncbi.nlm.nih.gov/pubmed/8083894>
24. Gomez RG, Ceballos L, Coburn M, et al. Consensus statement on bladder injuries. *BJU Int* 2004 Jul;94(1):27-32.
<http://www.ncbi.nlm.nih.gov/pubmed/15217426>
25. Chapple C, Barbagli G, Jordan G et al. Consensus on Genitourinary Trauma. *BJU Int* 2004 Jun;93(9): 1195-202.
<http://www.ncbi.nlm.nih.gov/pubmed/15180604>
26. Van der Horst C, Martinez Portillio FJ, Seif C, et al. Male genital injury: diagnostics and treatment. *BJU Int* 2004 May;93(7):927-30.
<http://www.ncbi.nlm.nih.gov/pubmed/15142139>
27. Gross M. Rupture of the testicle: the importance of early surgical treatment. *J Urol* 1969 Feb;101(2):196. [No abstract available]
<http://www.ncbi.nlm.nih.gov/pubmed/5765482>
28. Slater MS, Trunkey DD. Terrorism in America. An evolving threat. *Arch Surg* 1997 Oct;132(10):1059-66.
<http://www.ncbi.nlm.nih.gov/pubmed/9336502>
29. Caro D. Major disasters. *Lancet* 1974 Nov;30;2(7892):1309-10.
<http://www.ncbi.nlm.nih.gov/pubmed/4139541>
30. Weightl JA, Krantz BE, Ali J, et al. *Advanced Trauma Life Support Student Course Manual*. American College of Surgeons Committee on Trauma, 6th edn. Chicago, 1997.
31. *Treating Injury and Illness arising on Military Operations*. National Audit Office. February 2010.
32. Frykberg ER. Medical management of disasters and mass casualties from terrorist bombings: how can we cope? *J Trauma* 2002 Aug;53(2):201-12.
<http://www.ncbi.nlm.nih.gov/pubmed/12169923>
33. Jacobs LM Jr, Ramp JM, Breay JM. An emergency medical system approach to disaster planning. *J Trauma* 1979 Mar;19(3):157-62.
<http://www.ncbi.nlm.nih.gov/pubmed/458880>

8. ABBREVIATIONS USED IN THE TEXT

This list is not comprehensive for the most common abbreviations

| | |
|---------|---|
| AAST | American Association for the Surgery of Trauma |
| ATLS | advanced trauma life support |
| AVF | arteriovenous fistulae |
| BT | transperineal, interstitial, permanent prostate brachytherapy |
| BUN | blood urea nitrogen |
| CaPSURE | Cancer of the Prostate Strategic Urologic Research Endeavour |
| CT | computed tomography |
| DMSA | dimercaptosuccinic acid |
| EAU | European Association of Urology |
| EBRT | external beam radiotherapy |
| ED | erectile dysfunction |
| ePTFE | expanded polytetrafluoroethylene |
| FAST | focussed assessment with sonography for trauma |
| GR | grade of recommendation |
| HIV | human immunodeficiency virus |
| hpf | high-power field |
| IBT | iatrogenic bladder trauma |
| ICU | intensive care unit |
| IED | improvised explosive device |
| IRT | iarogenic renal trauma |
| ISS | injury severity score |
| IUhT | iatrogenic urethral trauma |
| IVP | intravenous pyelography/pyelogram |
| IVU | intravenous urography |
| KUB | kidney-ureter-bladder |
| LE | level of evidence |
| MRI | magnetic resonance imaging |
| MVA | motor vehicle accident |
| PCNL | percutaneous nephrolithotomy |
| rbc/hpf | red blood cells per high-power field |
| RUG | retrograde urethrogram |
| TOT | transobturator tape |
| TURB | transurethral resection of the bladder |
| TURP | transurethral resection of the prostate |
| TVT | tension-free vaginal tape |
| UPJ | ureteropelvic junction |
| US | ultrasound |
| WHO | World Health Organization |

Conflict of interest

All members of the Urological Trauma Guidelines working group have provided disclosure statements of all relationships that they have that might be perceived as a potential source of a conflict of interest. This information is publically accessible through the European Association of Urology website. This guidelines document was developed with the financial support of the European Association of Urology. No external sources of funding and support have been involved. The EAU is a non-profit organisation and funding is limited to administrative assistance and travel and meeting expenses. No honoraria or other reimbursements have been provided.

